

# Oral Health Care for Patients with Epidermolysis Bullosa - Best Clinical Practice Guidelines

Susanne M. Krämer<sup>1,2,3</sup>, María Concepción Serrano<sup>4</sup>, Gisela Zillmann<sup>1,3</sup>, Pablo Gálvez<sup>3</sup>, Ignacio Araya<sup>5</sup>, Nicolás Yanine<sup>5</sup>, Alonso Carrasco-Labra<sup>5</sup>, Patricio Oliva<sup>6</sup>, Romina Brignardello-Petersen<sup>5</sup> & Julio Villanueva<sup>5</sup>

<sup>1</sup>Department of Paediatric Dentistry, Facultad de Odontología, Universidad de Chile, Chile, <sup>2</sup>Unit Of Oral Medicine and Special Care Dentistry, UCL Eastman Dental Institute, London, UK, <sup>3</sup>DEBRA Chile, <sup>4</sup>Private practice, Valencia, Spain, <sup>5</sup>Evidence based Dentistry Unit, Facultad de Odontología, Universidad de Chile, Chile and <sup>6</sup>PhD candidate in Public Health and Biomedical Research Methods, Universitat Autònoma de Barcelona, Barcelona, Spain

*International Journal of Paediatric Dentistry* 2012; 22 (Suppl. 1): 1–35

**Objective.** To provide the users with information on the current best practices for managing the oral health care of people living with EB.

**Methods.** A systematic literature search, in which the main topic is dental care in patients with Epidermolysis Bullosa, was performed. Consulted sources, ranging from 1970 to 2010, included MEDLINE, EMBASE, CINAHL, The Cochrane Library, DARE, and the Cochrane controlled trials register (CENTRAL). In order to formulate the recommendations of the selected studies the SIGN system was used. The first draft was analysed and discussed by clinical experts, methodologists and patients representatives on a two days consensus

meeting. The resulting document went through an external review process by a panel of experts, other health care professionals, patient representatives and lay reviewers. The final document was piloted in three different centres in United Kingdom, Czech Republic and Argentina.

**Results.** The guideline is composed of 93 recommendations divided into 3 main areas: 1) Oral Care - access issues, early referral, preventative strategies, management of microstomia, prescriptions and review appointments-, 2) Dental treatment: general treatment modifications, radiographs, restorations, endodontics, oral rehabilitation, periodontal treatment, oral surgery and orthodontics-, and 3) Anaesthetic management of dental treatment.

**Conclusions.** A preventive protocol is today's dental management approach of choice.

## INTRODUCTION

DEBRA International is a worldwide network of national groups working on behalf of those affected by the genetic skin blistering condition, epidermolysis bullosa (EB).

Epidermolysis bullosa is a rare disease with multiple oral manifestations, which requires a special approach from the dental point of view. Because of its low prevalence, many dentists have limited knowledge of the disease. The scientific literature regarding oral health care of people living with EB is relatively scarce. This makes it difficult for dentists with no experience in treating people with EB to know how

to approach them in a safe manner given all the special care these patients might need.

As part of their vision for working to ensure access to the best quality support and medical care for people living with EB, DEBRA International entrusted the development of Clinical Guidelines to health care professionals with significant experience in EB around the world.

It became necessary to gather experts from different centres around the world to discuss the different treatment alternatives and to work towards establishing the best clinical practice guidelines. These guidelines contain the appropriate precautions that people with EB might require to receive optimal oral health care.

The present guidelines on dental care for people living with EB have been developed by an international team of dentists, using a standard methodology based on a systematic review of the currently available scientific evidence.

### Correspondence to:

Susanne Marie Krämer, Department of Pediatric Dentistry, Facultad de Odontología, Universidad de Chile. Sergio Livingstone 943, Independencia, Santiago, Chile. Email: skramer@u.uchile.cl

These guidelines contain a chapter on general information on dental care of patients with EB, followed by a chapter explaining the precautions that should be taken into account when treating patients with each subtype of EB, as well as recommendations for dental treatment. The appendix includes a glossary, general information on EB, and a description of its oral manifestations.

**1.1 AIM**

To provide the users with information on the current best practices for managing the oral health care of people living with EB.

**1.2 USERS**

Specialists in Paediatric Dentistry, Special Care Dentistry, Orthodontics, Oral and Maxillofacial Surgery, Rehabilitation and General Dental Practitioners, Dental hygienists, Paediatricians, Dermatologists, Dietitians, parents, and those living with inherited epidermolysis bullosa.

**1.3 TARGET GROUP**

These guidelines can be applied to all patients diagnosed with epidermolysis bullosa. As such, the guideline considers information for all four major types of EB: EB simplex, junctional EB, dystrophic EB, and Kindler syndrome.

**1.4 Method used for Formulating the Recommendation**

To formulate the recommendations, from the selected studies, the SIGN Guidelines were used.

**LEVELS OF EVIDENCE**

1++	High quality meta-analyses, systematic reviews of RCTs, or RCTs with a very low risk of bias
1+	Well-conducted meta-analyses, systematic reviews, or RCTs with a low risk of bias

1-	Meta-analyses, systematic reviews, or RCTs with a high risk of bias
2++	High-quality systematic reviews of case-control or cohort studies High-quality case-control or cohort studies with a very low risk of confounding or bias and a high probability that the relationship is causal
2+	Well-conducted case-control or cohort studies with a low risk of confounding or bias and a moderate probability that the relationship is causal
2-	Case-control or cohort studies with a high risk of confounding or bias and a significant risk that the relationship is not causal
3	Nonanalytic studies, for example, case reports, case series
4	Expert opinion

**GRADES OF RECOMMENDATION**

*Note: The grade of recommendation relates to the strength of the evidence on which the recommendation is based. It does not reflect the clinical importance of the recommendation.*

<b>A</b>	At least one meta-analysis, systematic review, or RCT rated as 1++, and directly applicable to the target population; or A body of evidence consisting principally of studies rated as 1+, directly applicable to the target population, and demonstrating overall consistency of results
<b>B</b>	A body of evidence including studies rated as 2++, directly applicable to the target population, and demonstrating overall consistency of results; or Extrapolated evidence from studies rated as 1++ or 1+
<b>C</b>	A body of evidence including studies rated as 2+, directly applicable to the target population, and demonstrating overall consistency of results; or Extrapolated evidence from studies rated as 2++
<b>D</b>	Evidence level 3 or 4; or Extrapolated evidence from studies rated as 2+

**GOOD PRACTICE POINTS**

<input checked="" type="checkbox"/>	Recommended best practice based on the clinical experience of the guideline development group
-------------------------------------	---

Fiftieth Guideline Developer’s Handbook, NHS Scottish Intercollegiate Guidelines Network SIGN. Revised Edition January 2008.

## 2 Oral care for patients with inherited Epidermolysis Bullosa<sup>A</sup>

### 2.1 Introduction

**D** A preventive protocol is today's dental management approach of choice<sup>1-3</sup>.

The approach to dental treatment for patients with epidermolysis bullosa (EB), in particular for those with the more severe types, has changed dramatically over the last 30 years. Crawford *et al.*<sup>4</sup> considered extraction of all teeth to be the treatment of choice for patients with RDEB. Two decades later, in 1999, Wright<sup>5</sup> declared that it was possible to manage dental abnormalities successfully with a combination of anaesthetic and restorative techniques. Recently, Skogedal *et al.*<sup>2</sup> demonstrated that caries can be successfully prevented in patients with RDEB by continuous follow-up aimed at dietary advice, oral hygiene habits, frequent professional cleaning, and fluoride therapy.

### 2.2 Importance of oral preventive care and dental treatment<sup>B</sup>

- 1) To prevent and treat pain and infection. This is important considering that patients with oral pain will reduce their nutritional intake.
- 2) To improve aesthetics and self-esteem.
- 3) A healthy dentition allows patients to improve their nutritional state<sup>6</sup>, as they will be able to chew better. Maintaining a functional dentition reduces the potential for oral and oesophageal soft tissue damage through more efficient mastication<sup>7,8</sup>; however, a nutritional consultation is important, as advice must be given on the nutritional content of the diet and the consistency of the food.
- 4) Improved phonetics when anterior teeth are restored, allowing for better positioning of the tongue.

- 5) Improved swallowing: doing mouth opening exercises strengthens the muscles and allows for better access for routine hygiene.
- 6) Maintaining a harmonious relationship between teeth stabilizes the occlusion for better function and aesthetics and allows better hygiene.

### 2.3 Access to dental clinic

- The clinic must be of easy access for patients using wheelchairs and walking frames.
- Allow patients to accommodate on their own giving them enough time. Do not try to assist them if you are not aware of the areas where they have wounds.
- If the patient has to travel a long distance to attend the specialist dentist in the EB unit, a shared care approach can be arranged with a local dentist, who can provide more regular preventative care.

Access to dental care can be a challenge for some patients. Even though in most developed countries it is guaranteed, it is still a privilege for many patients around the world.

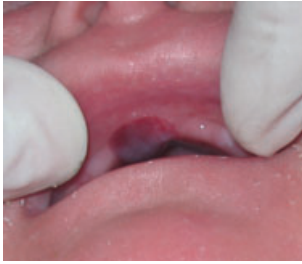There is a lack of knowledge about the disease in the dental profession<sup>9</sup> and other healthcare professionals. Dental care can be complicated by the fears of both the patient and the dentist<sup>10</sup>. Allow yourself plenty of time. Even the most simple procedures, such as an oral exam, takes longer because of the limited access, discomfort, or fear of developing blisters secondary to soft tissue manipulation.

### 2.4 Early referral

Members of the multidisciplinary team should refer patients to the dentist before oral problems present, as early referral and close follow-up are the key to keeping patients as healthy as possible from the oral point of view (Image 1).

<sup>A</sup>The Oral manifestations of EB can be found in page 22.

<sup>B</sup>This list was ordered according to the preferences of the patients and their representatives.

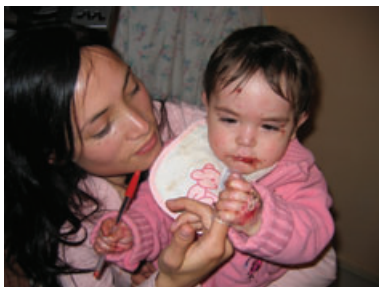

**Image 1** Early diagnosis and education to parents on bullae management.

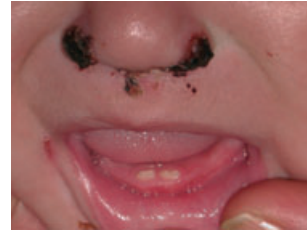Patients with EB should be referred to the dentist for the first consultation at the age of 3–6 months. The first consultation should be aimed at:

- (a) Education of the parents and caregivers: counselling on diet (including sugar-free medications), oral hygiene routines, fluorides, technical aids, and oral manifestations of EB. This preventative advice should be provided even before the teeth erupt (Image 2).
- (b) Early diagnosis of enamel abnormalities such as those seen in junctional EB (JEB). This is possible as soon as the first primary tooth erupts (Image 3).
- (c) Early diagnosis of tooth crowding, mainly in recessive dystrophic EB (RDEB).
- (d) Early diagnosis of incipient caries lesions.

Patients with EB should be referred to a dentist as early as possible to identify any feature related to EB that needs special attention, for example, generalized enamel hypoplasia<sup>5,10-13</sup>. This enables dentists to start preventive programmes and reduces the risk of developing dental diseases<sup>14</sup>. Many case reports have shown that patients visit the dentist only when they already have several carious lesions or pain<sup>7,11,15,16</sup>.



**Image 2** Early oral hygiene instruction.



**Image 3** Early diagnosis of Generalized Enamel Hypoplasia in JEB.

### 2.5 Oral bullae and ulcerations

Although oral bullae, ulcers, and erosions are the most common oral feature of EB, there is only one published study of a therapy for these oral lesions. Marini *et al.*<sup>17</sup> found that sucralfate suspension reduced the development and duration of oral mucosal blisters and ulcers, reduced the associated oral pain, and improved plaque and gingival inflammation indices<sup>17</sup>.

### 2.6 Preventative Strategies

*Oral Hygiene.* At home – Concern is expressed by some patients, parents, and dentists regarding the use of tooth brushes and potential damage to the oral mucosa.

**D** Tooth brushing is possible in all patients with EB, even in patients with the severe generalized RDEB subtype. The following suggestions can help determine the appropriate toothbrush for each patient:

- (a) Small head<sup>5,7,8,11,13</sup>.
- (b) Soft bristle<sup>5,8,11,13,18</sup>.
- (c) Bristles can be further softened by soaking them in warm/hot water<sup>10,13</sup>.
- (d) In patients with severe microstomia, short bristles are indicated to access occlusal surfaces of molars. For this purpose, bristles can be cut. If bristles are cut, one needs to ensure that they remain soft and do not harm the tissue.
- (e) Special adaptations of the toothbrush handle can be advantageous for patients with pseudosyndactyly and manual dexterity problems (Images 4).
- (f) Parents or caregivers are advised to assist children, to improve plaque removal, and

helping to reduce the risk of tissue damage<sup>7</sup>.

- (g) A manual toothbrush may be preferable to an electric brush<sup>7</sup> (There is no evidence to support this statement. This reflects an author's opinion).
- (h) Special toothbrushes, for example, Collis Curve (TM) toothbrush, might be a good option for patients with RDEB, but more research on its efficiency is needed (Images 5).
- (i) Cotton buds (cotton swabs), disposable mini brushes, clean cotton cloth, or gauze can be used to clean the teeth if a patient is temporarily not able to brush because the mouth is very sore.

**D** Rinsing with water during the day, particularly after meals<sup>10,19</sup>, also helps oral hygiene as it improves removing food debris or sugar deposits.

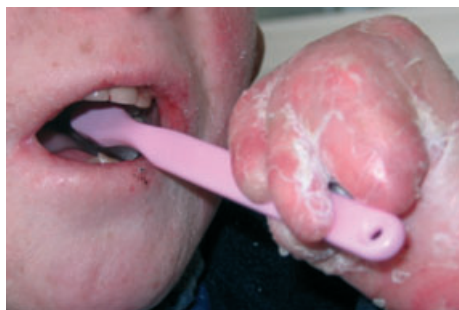Disclosing solution or tablets to help identify dental plaque are a useful tool to help patients assess their effectiveness when brushing their teeth. They can be used by all patients with EB.

**D** *Professional Hygiene.* Gentle and careful ultrasonic scaler and polish techniques can be used in all patients, including severe RDEB<sup>11</sup>. Haemorrhagic bulla can appear because of vibration on the mucosa. If this happens, they should be drained.

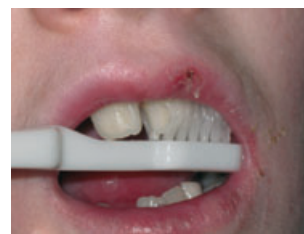#### *Adjuvant therapies.*

##### Chlorhexidine

**D** Chlorhexidine 0.12% has been widely advocated for oral disease prevention in



**Image 4** Patient with RDEB and pseudosyndactyly performing oral hygiene.



**Image 5** Collis Curve (TM) toothbrush brushing the palatal and buccal sides of the tooth simultaneously.

patients with EB<sup>5,7,10,11,16,19,20</sup>. It has shown to be effective for candida while ineffective for caries control.

- A variety of application methods have been used, including mouthwashes, swabs, sprays, gels, and topical varnish applications.
- An example of a preventative treatment protocols is as follows: a rinse two times a day for 2 weeks every 3 months.

**D** Alcohol-free formulations are advised in patients with oral lesions<sup>8,10,11</sup>.

##### Fluoride

**D** Topical applications of high-dose fluoride varnish are suggested every 3 months in patients with high caries risk or at each dental visit<sup>5,7,19</sup>.

**D** For children resident in nonfluoridated communities, the importance of daily fluoride supplements has been highlighted<sup>10</sup>.

Fluoride can also be prescribed as a gel preparation or mouth wash. Gel preparations can be applied with a toothbrush, in a custom-made plastic tray<sup>10</sup> or with cotton rolls. Mouth wash formulations should be alcohol free in patients with oral lesions. These 0.05% and 0.2% fluoridated solutions can also be applied topically with a cotton bud on all teeth once a day<sup>21</sup>.

*Dietary modifications.* As indicated previously, the dietary habits/requirements of patients with EB may increase the risk of caries.

**D** A dietary caries-prevention programme should be instigated at early age<sup>16,18</sup>.

- It is essential that dentists and nutritionists collaborate on an appropriate programme for each patient, as opposed to giving contradictory advice that may confuse patients and parents/guardians.

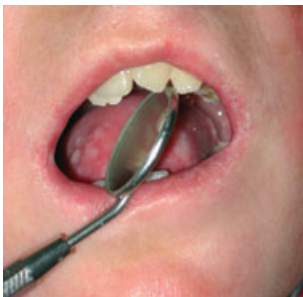#### *Fissure sealants and other aids.*

- D** Sealing fissures and fossae has been recommended, as oral hygiene and other preventive measures can be difficult to perform<sup>10,13,22</sup>. Some clinical experts, however, have apprehensions regarding this advice, as the technique is very sensitive and may not be an option for some patients because of limited cooperation, compromised access, and difficult long-term follow-up.
- Other remineralization techniques, such as Recaldent (CPP-ACP), can also be used for the noninvasive management of early caries lesions in patients with EB.

#### *2.7 Microstomia*

- Patients with severe generalized RDEB should perform daily exercises to improve/maintain a good mouth opening. This can be performed, for example, during dressing changes.
- Improving mouth opening also favours phonation and swallowing.
- D** Performing exercises half an hour before dental treatment helps improving access<sup>22</sup>.

Limited mouth opening has been reported as the greatest clinical difficulty for providing dental treatment<sup>23,24</sup> as well as complicating intubation (Image 6)<sup>25</sup>. In this context, the



**Image 6** Microstomia makes the access to the oral cavity difficult.

consulted literature provides no definitive solutions. Slight increments in the maximum oral aperture have been obtained with mechanical techniques. Four techniques have been described.

In one patient, resin plugs of progressively increasing calibre increased maximal mouth opening from 19 to 23 mm after 10 min of exercise and to 30 mm at the end of a treatment session<sup>22</sup>. Unfortunately, this parameter returned to the initial values on discontinuing mechanical therapy.

Other suggestions include daily exercises with wooden spatulas<sup>26</sup>, mouth trainer, and threaded acrylic cone.

#### *2.8 Prescriptions*

- When prescribing medications in tablet form to patients with RDEB, it is important to consider that swallowing them could be difficult because of oesophageal stenosis or could cause oesophageal trauma. Therefore, prescriptions should be in soluble or liquid form. If sugar-free preparations are not available, parents should be advised of the sugar content and advised ideally to brush or at least rinse the child's teeth with water directly after administration of the medication to reduce the risk of decay.

#### *2.9 Review appointments*

- D** Frequency of dental review should be scheduled on an individual basis according to the amount of plaque present and risk of caries. Every 3–6 months may be sufficient for some patients, and for others, monthly appointments may be necessary<sup>3,5,15,22,27</sup>. The review sessions should be aimed at<sup>3,7,15,19,22</sup>:
  - (a) Caries prevention/early diagnosis.
  - (b) Professional plaque removal.
  - (c) Topical fluoride application.
  - (d) Dietary advice.
  - (e) Review progress or deterioration of patient's oral condition.

- D** As the predisposition to develop intra-oral squamous cell carcinoma (OSSC)

increases with age, cancer screening must be considered a very important aspect of the review appointment in patients with RDEB from the second decade on<sup>19,28</sup>.

- Any unusual ulcer or white or red patches should be biopsied to ensure that these do not represent pre-cancer or cancer in the mouth.

Frequent recall visits have shown to be useful to maintain dental health in patients with EB<sup>6,7,15</sup>. There are examples of patients who previously had extensive carious teeth who

remained caries free when attending frequent review appointments<sup>6,7</sup>. On the other hand, clinical cases have been reported showing that patients who failed to attend the review visits developed several caries within 2 years, despite a preventive programme being explained<sup>11,16</sup>.

As many patients have to commute long distances, review appointments should be scheduled together with other health care appointments. A shared care approach can be considered.

### 3 Dental treatment

#### 3.1 Treatment modifications and precautions

Even though patients with milder oral involvement do not require many treatment modifications, a careful approach benefits every patient. Patients with the severe generalized RDEB subtype of EB require the most specific precautions during treatment to minimize soft tissue damage.

##### 3.1.1 EB simplex (EBS).

**D** Most authors agree that routine dental treatment can be provided<sup>5,22,29</sup>.

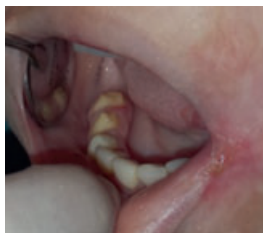Clinicians should ask about history of mucosal fragility because manipulation can precipitate lesions in mildly affected patients<sup>5</sup>. Although this has never happened to the members of the expert consensus; we recognize that EB is very diverse and that it could happen.

##### 3.1.2 Junctional EB (JEB).

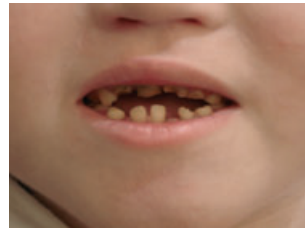
**D** Dental management does not require many modifications<sup>4</sup>; however, a careful approach is advised as tissue manipulation can produce oral ulceration (Image 7).

This group requires an aggressive preventive programme and frequent visits to the dentist as they present with generalized enamel hypoplasia, leading to an increased risk of cavities and severe attrition.

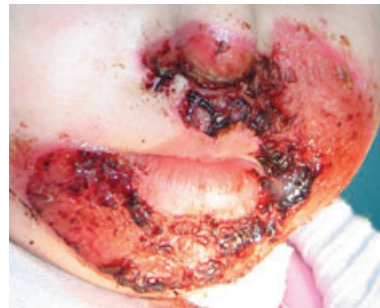Mucosal and skin fragility vary considerably between subtypes of JEB and patients, and the avoidance of adhesive contact with the skin and careful manipulation is always advised. Following the suggestions listed in 'Recessive DEB' can be of help for these patients as well.



**Image 7** Ulcer on the tongue and commissure of a patient with JEB.



**Image 8** Five-year-old patient with JEB and no perioral lesion.



**Image 9** Two-year-old patient with JEB and severe perioral granulation tissue.

This group of patients will require a special dental rehabilitation plan, as they present with generalized enamel hypoplasia (Images 8 and 9).

##### 3.1.3 Dominant DEB (DDEB).

**D** Patients with DDEB are able to receive routine dental treatment with little or no modifications<sup>28</sup>. Nevertheless, a careful approach is still advised as tissue manipulation can produce oral ulceration.

There is a report of a patient who has been wearing dentures for several years without difficulties<sup>4</sup>.

##### 3.1.4 Recessive DEB (RDEB).

Patients with the severe generalized RDEB subtype of EB require several treatment modifications and a careful approach to avoid as much tissue damage as possible. Management of these patients ideally requires a well-organized multidisciplinary team approach<sup>27,30</sup> with good communication involving case discussion.

#### 1. Lubrication

**D** Lips should always be lubricated with Vaseline®/petrolatum or other



appropriate lubricants before any procedure is performed to reduce adherence and reduce shearing forces that lead to tissues separation and lesions formation<sup>1,5,18,27,31</sup>.

There have been reports suggesting the lubrication of the buccal mucosa and instruments as well, but the consensus group believes this does not benefit the patient and makes treatment more difficult.

In the operating room, a water-soluble lubricant should be used instead of petrolatum because it is not flammable.

## 2. Suction tip

**D** Bullae formation or epithelial sloughing can occur upon contact with the suction tip<sup>1</sup>. It is suggested to lean the suction tip or saliva ejector upon hard tissue, that is, on occlusal tooth surface or on a wet cotton roll<sup>32</sup> (Image 10).

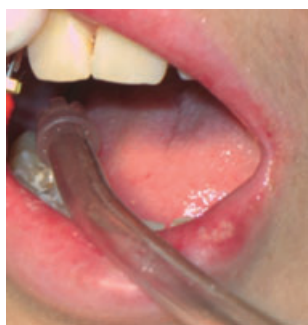Avoid use of high vacuum suction as this could cause sloughing of extensive areas of tissue.

## 3. Bullae

**D** Blood- or fluid-filled bullae that occur during treatment should be drained with a sterile needle or by a cut with scissors to avoid lesion expansion because of fluid pressure<sup>13,22,23,33</sup>.

## 4. Pressure

**D** Extreme care of fragile tissues is important. To handle tissues, a little pressure (compressive forces) can be applied, but no sliding movements (lateral traction or other shear forces) should be used, as these can cause tissue sloughing<sup>5,11,23</sup>.



**Image 10** Suction tip leaned on tooth surface to avoid mucosal sloughing.

## 5. Air syringe

**D** Can be used but should be managed carefully<sup>11</sup>. Air-filled bullae can occur. If this happens, they have to be drained.

## 6. Instruments

**D** Because of limited access, it is easier to use paediatric size instruments<sup>13</sup>.

A laryngeal mirror can also be helpful in patients with severe microstomia. Flat malleable retractors are useful for separating the cheeks, as they spread force over larger area and can protect tissue if having to prep a tooth for restorative treatment. They come in various widths and are typically available in hospital operating rooms.

## 7. Isolation

Relative isolation: When using cotton rolls, it is advised to lubricate them with Vaseline®/petrolatum or other aqueous products for intraoral lubrication before placing them inside the mouth. When removing them, they must be soaked with water.

Consider reducing the size of the cotton rolls so they can fit in limited spaces.

Complete isolation: Rubber dam can be used with or without clamps, aided with wooden wedges. Use with caution as the placement and position of the clamp, and the rubber dam against the lip and cheeks can cause blisters.

## 8. Visual access

In severe microstomia, it is easier to separate the lip using the handle of the mirror instead of the mirror itself, or flat malleable retractors as explained before.

When possible, consider use of head light.

## 9. End of session

At the end of every clinical session, it is important to check for fluid-filled blisters and drain them. It is also important to check and remove any remnants of dental materials in the sublingual space or vestibule, as the patients have ankyloglossia and cannot clear the mouth easily. This can be carried out with a wet cotton roll.

### 3.1.5 Kindler Syndrome:

**D** A careful approach is advised, as mucosal sloughing can form following dental treatment such as scaling<sup>34</sup>.

The scarce literature available suggests periodontal health as main area of concern for dental therapy<sup>34,35</sup>.

### 3.2 Dental radiographs:

In patients with EBS, JEB, DDEB, and Kindler syndrome, all diagnostic techniques can be used with no or little technique modification.

**D** In patients with severe generalized RDEB, periapical technique has been proved to be extremely difficult – especially in the posterior area – because of microstomia, ankyloglossia, and scarring of the sublingual area. Orthopantomography (panoramic) is the radiograph of choice<sup>32</sup>.

Other techniques that can also be helpful and diagnostic are as follows:

- Bitewings using small films.
- Some digital panoramic radiographs have extraoral bitewings capabilities making them a good option for patients with limited access.
- As an alternative, an occlusal technique can also be used for anterior teeth or lateral oblique for mandibular posterior teeth.

**D** If periapical radiographs are required in RDEB, care must be taken not to damage the mucosa<sup>11</sup>. Lubrication of the film packet has been advised to avoid tissue damage<sup>36</sup>.

### 3.3 Restorations

Restorative treatment can be difficult in patients with RDEB because of microstomia, soft tissue fragility, and complex anaesthetic management<sup>37</sup>.

**D** There are no contraindications to the use of conventional dental materials<sup>5,38</sup>.

The restorative material to be used will depend on the possibility of achieving

isolation, carries risk, and cultural and economic factors. The use of stainless steel crowns should be considered.

The atraumatic restorative treatment (ART) technique can be used in difficult or special circumstances.

**D** Restorations and dentures should be carefully adapted and highly polished to lessen the risk of iatrogenic oral mucosal blisters and ulcers<sup>18</sup>.

**D** Iatrogenic blisters can develop after treatment even if all precautions are in place<sup>22</sup>.

**D** Soft tissue lesions resulting from restorative treatment typically heal in one to two weeks and require no specific treatment<sup>32</sup>.

If required, analgesics can be prescribed.

### 3.4 Endodontics

**D** Root canal treatment (endodontic treatment) can be performed in all patients, unless there is no access because of limited mouth opening<sup>32</sup>.

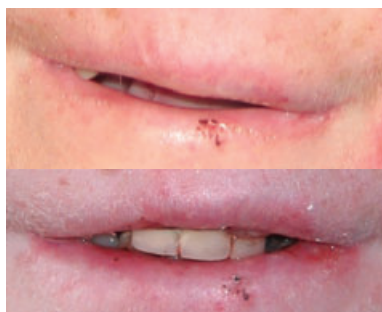In patients with severe microstomia, access to the pulp chamber might need to be modified. For example, anterior teeth might need vestibular access.

For determining root canal working length in patients with RDEB and severe microstomia, it is best to use electronic apex locators or, if unavailable, a panoramic radiograph (as periapical radiographs are difficult to take).

Concern has been raised regarding the use of hypochlorite when isolation is not ideal. The experience of the working group is that there are no major problems using this agent.

### 3.5 Impression taking

Although there are no reports of any adverse events (i.e., mucosal damage), impressions should be taken with special care in RDEB<sup>32,39,40</sup>.



**Image 11** Before and after fixed crown restoration.

- All type of impression material can be used.
- D** Microstomia can be a real challenge. As an alternative to stock impression trays, specially cut topical gel application trays and custom-made acrylic trays have been proposed<sup>18</sup>. Another alternative is to do a first impression with hard (putty) silicone and to use this as a tray adding light body silicone on a second step.
- If the cervical margin is subgingival, a gingivectomy may be needed. For information on this matter, consult the Gingivectomy section.
- D** Computer-generated stereolithographic template can be a noninvasive harmless impression solution for surgical and prosthodontic implant planning and placement in RDEB<sup>24</sup>.

### 3.6 Oral rehabilitation

Oral rehabilitation can be fixed or removable depending on the health system and financial possibilities.

- Whenever possible, fixed rehabilitation is advised.

#### A. Fixed rehabilitation.

- D** The use of stainless steel crowns has been reported as a successful approach in children with RDEB and JEB<sup>4,5,22,41</sup>.
- D** Successful oral rehabilitation with fixed bridges has been reported in several patients with severe generalized

RDEB<sup>11,18</sup>, improving aesthetics, oral function, and enhancing patients' confidence (Image 11)<sup>18</sup>.

- In cases with generalized enamel hypoplasia, restoration of the entire dentition with full crowns may be necessary.

This treatment has to be planned carefully and discussed with the parents and the patient, as it may consist of several stages until full permanent dentition has been established and restored<sup>33,42</sup>.

#### B. Removable dentures.

The tolerance to bear tissue-supported dentures depends on the degree of mucosal fragility of each EB subtype and patient.

- D** Reports of patients successfully tolerating these types of dentures include patients with EBS, JEB, DDEB, and pre-tibial RDEB<sup>4,22,43,44</sup>.
- Few patients with RDEB can bear dentures if the buccal margins are adapted and the retainers are flat.
- D** Overdentures have been described as a practical, economic, nonsurgical treatment option for patients with JEB and generalized hypoplastic enamel who present with failure of eruption<sup>43</sup>. Careful follow-up is needed because of the high risk of caries.

#### C. Implant rehabilitation.

- C** Fixed prostheses are the rehabilitation technique of choice<sup>31,39</sup>.
- D** Short dental arch rehabilitation scheme is advised<sup>39,40</sup>.

A variety of implant supported prostheses can be considered for complete denture rehabilitation, such as fixed bridges or overdentures<sup>31,39,40</sup>. The level of satisfaction after implant therapy in one series was slightly higher in the fixed prosthesis group ( $n = 3$ , mean 9.6) than in the overdenture group ( $n = 3$ , mean 8.8). Oral mucosal ulcerations were observed in areas in contact with overdentures, whereas in patients with fixed dentures, the tissues appeared healthier<sup>31</sup>. Limited mouth opening, limited posterior

space, and oral hygiene difficulties may make it necessary to use a short dental arch rehabilitation scheme<sup>39,40</sup>.

### 3.7 Periodontal treatment

- D** Periodontal treatment can be performed in all patients with EB. Special care must be taken in patients with RDEB, as there might be substantial bleeding during the procedure<sup>11,32</sup>.

## 3.8 Oral Surgery

**3.8.1 Suturing.** There has been debate in the literature about the feasibility of suturing after oral surgery in patients with EB<sup>7,9,23,27,41,45</sup>.

- Sutures can be used safely in all patients with EB, but need careful placement.

### 3.8.2 Gingivectomy.

- Gingivectomy using a laser or electric scalpel is the technique of choice. In patients with Kindler syndrome, this technique may be needed to remove hyperplastic gingival papillae.

**3.8.3 Vestibuloplasty.** Severe obliteration of the vestibule can cause difficulty in eating<sup>46</sup>, performing oral hygiene<sup>46</sup>, providing dental treatment, and reduces food clearance because of reduced mobility.

- Periodontal plastic surgery and vestibuloplasty to deepen the vestibule or to restore the alveolar ridge height has been reported in two patients with dominant dystrophic EB (DDEB)<sup>46,47</sup>. The consensus of experts has limited but positive experience on this kind of surgery in patients with RDEB. This surgery is recommended when required, that is, when the obliteration affects the patient's quality of life or oral function.
- D** Inserting a soft acrylic stent extending to the newly established vestibule avoids fusion of the connective tissue layers and allows time for epithelium migration on both surfaces<sup>47</sup>.

### 3.8.4 Biopsy.

- Biopsies of oral tissues may be required when a squamous cell carcinoma (SCC) is suspected.

**3.8.5 Surgical Extractions.** Contemporary oral health care is targeted at prevention of oral disease, but some patients still require extractions because of severe caries or the need for orthodontic care that involves severe dental crowding. Surgical/difficult extractions should be performed by an oral surgeon.

- D** When planning surgical extractions, especially if multiple extractions are needed, it is advisable to consult the patient's physician as profound anaemia could complicate the dental surgery<sup>30</sup>.

- D** For multiple extractions, it has been suggested to extract first the anterior teeth (i.e., from premolar to premolar) and then the molars to allow optimal access<sup>30</sup>.

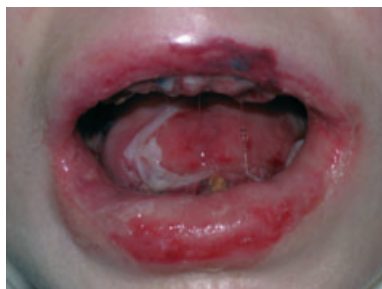- D** An atraumatic technique should be used, making firm and safe mucosal incisions to prevent bullae formation<sup>10,23</sup>.

- D** Haemostasis can be achieved with gentle pressure using gauze packs<sup>9,41</sup>. These should be wet to avoid tissue adherence.

Some authors have reported the extraction of healthy third or even second permanent molars in patients with severe generalized RDEB to improve or facilitate oral hygiene<sup>2,48</sup>. There is controversy among different authors about this intervention. Severe tooth crowding<sup>12,22,49</sup>, reduced alveolar arches secondary to growth retardation<sup>8,50</sup>, and severe microstomia<sup>1,7,22,23,31,45,51,52</sup> are described in patients with severe generalized RDEB, which would justify preventive extractions. However, nowadays most patients receive dietetic advice that optimizes nutrition and growth. They receive orthodontic treatment (serial extractions) and are advised on exercises to improve microstomia. Therefore, preventive extractions of permanent molars need to be assessed very carefully on an individual basis.

**Perioperative complications:** Despite attempts to use as gentle manipulation as

possible and all the special precautions, mucosal sloughing and blister formation have been reported after almost every surgical extraction in patients with severe RDEB<sup>1,9,22,30,41</sup>. Blisters can arise at the angles of the mouth, lips, vestibule, tongue, and any sites of manipulation (Image 12); some measuring up to 4 by 3 cm<sup>1,30</sup>. In some instances, they might only be noticed by the patient or carer only on the second post-operative day<sup>9</sup>.



**Image 12** Bullae, ulcers, and mucosal sloughing after surgical extractions.

**Post-operative complications:** Despite the potential for extensive mucosal damage during surgery, post-operative complications are rare<sup>9,30,53</sup>. Healing of the oral tissues occurs gradually after one to 2 weeks<sup>16,21,41</sup>. Healing of the alveolar sockets seems to be uneventful<sup>6,9</sup>. Nevertheless, there is a suggestion that scarring of the oral commissure can be accentuated after surgery<sup>1,9</sup>. The use of post-operative antibiotics will depend on each individual case.

### 3.8.6 Osseointegrated implants.

- D** To avoid destruction of the atrophic residual alveolar ridges of the maxilla, an osteotome technique is advised<sup>23,31</sup>.
- D** Surgical management can be complicated by bleeding and bullae<sup>23,31,54</sup>.
- D** When needed, bone grafts can be placed simultaneously with implants to reduce the number of surgical interventions and, therefore, mucosal/skin damage<sup>54</sup>.

Successful rehabilitation using dental implants has been reported in patients with

generalized RDEB, non-Herlitz JEB, and RDEB-I<sup>5,23,31,55</sup>. The most extensive report encompasses 38 dental implants with a success rate of 97.9% with a follow-up of 1–9 years (average 5.5). Peri-implant mucosa remained in good condition in all patients<sup>24,31,54</sup>. It has been reported that after rehabilitation, patients improved their ability to chew, swallow, and their quality of life<sup>23,31,39,40</sup>. Block and particulate allograft and autografts have been used successfully in patients with RDEB<sup>54</sup>. For information on stereolithography, see Impression taking.

These results are encouraging and dental implants seem a possible solution for edentulous patients with EB and mucosal fragility. It is important to note, however, that patients with RDEB and JEB have been shown to have lower bone mineral density scores<sup>56</sup>. There has been clinical evidence of bone atrophy during implant surgery as well<sup>23,31,40</sup>.

When planning this type of rehabilitation, advice from the medical team should be sought, as extensive surgery might need to be delayed or discouraged because of concomitant pathology as, for example, severe anaemia or poor prognosis SCC.

### 3.9 Orthodontics

- D** Orthodontic treatment typically only requires minor modifications in patients with EBS, JEB, and DDEB<sup>5</sup>. Patients with EBS Dowling–Meara, however, can have more mucosal fragility requiring the precautions indicated below.
- For patients with RDEB, we strongly recommend serial extractions to prevent dental crowding, as this contributes to high caries risk and periodontal disease.
  - a.** The aim of orthodontics in RDEB should be to obtain tooth alignment.
  - b.** Serial extractions should be performed at the appropriate stage of dental development.
  - c.** A risk-benefit analysis should be performed on an individual basis to avoid the need for repeated general anaesthetic for serial extractions. These procedures should

ideally be performed with behavioural management techniques and local anaesthesia.

In patients with RDEB, it is possible to achieve tooth movement using fixed orthodontics, such as to: (1) correct a one tooth cross-bite, (2) close diastema, and (3) align the anterior teeth.

A tooth-borne removable appliance may also be possible, for example, inclined, anterior bite plane to correct a cross-bite.

**D** To prevent lesions on the soft tissues, orthodontic wax/relief wax can be applied on the brackets<sup>48</sup>.

## 4 Anaesthetic management

All kinds of dental treatment for patients with EB can be provided under local anaesthesia, conscious sedation, or general anaesthesia. The decision on which type of anaesthetic management approach to choose must be agreed between the patient and the dentist based on the risks, advantages, and disadvantages of each technique, as well as the availability of specialized services. It is important to highlight that conscious sedation should not be performed in-office on patients with potential for compromised airway or difficult intubation.

For patients with mild forms of EB and for small, atraumatic procedures, using local anaesthesia is the technique of choice. General anaesthesia can be indicated for some extensive procedures in patients with severe forms of EB, but the support of an experienced team is crucial.

### 4.1 Local anaesthesia

- Topical anaesthesia in gel form can be used normally.
- D** To avoid blister formation, the anaesthetic solution must be injected deeply into the tissues and at a slow rate, to avoid the liquid causing mechanical separation of the tissue<sup>5,23,31</sup>.
- Iatrogenic blisters may develop following local anaesthesia injection<sup>6,11,18,21–23,57</sup>. If this happens, the lesions have to be drained.
- Post-operative instruction must highlight that the patients should not bite, rub, or traumatize their lip while under the effect of local anaesthesia.

The main benefits of local anaesthesia are that it maintains airway patency and provides prolonged post-operative pain relief. Examples of successful treatments provided under local anaesthesia include multiple extractions, implants, root canal treatment, and restorations<sup>6,16,23</sup>.

Some authors suggest that less mucosal damage is produced when patients are treated under local anaesthesia when compared to general anaesthesia.

### 4.2 General anaesthesia

- D** When planning a procedure under general anaesthesia, the patient's MD/GP should be consulted<sup>13</sup>.
- The availability of an anaesthetic team with experience in EB is crucial. If this is not available, the use of local anaesthesia should be considered.

Treatment under general anaesthesia allows the provision of extensive reconstructive dental treatment and multiple extractions regardless of the severity of soft tissue fragility and microstomia present<sup>5,7</sup>. The fact that the patient will be asleep, however, does not mean that the procedure will be easy to perform. Patients with severe fragility will still develop intra-operative generalized mucosal sloughing secondary to retraction and minor trauma of the procedure itself<sup>1,7,36</sup>. Oral surgery and restorative procedures can be combined with other surgical procedures, as for example, oesophageal dilatation<sup>1</sup>. As stated previously, a water-soluble lubricant should be used instead of petrolatum in the operating room because it is not flammable.

## 5 Summary of recommendations

- D** A preventive protocol is today's dental management approach of choice<sup>1,2</sup>.

### Early referral

- Patients with EB should be referred to the dentist for the first consultation at the age of 3–6 months.

### Oral hygiene

- D** Tooth brushing is possible in all patients with EB, even in patients with the severe generalized RDEB subtype. The following suggestions can help determine the appropriate toothbrush for each patient:

- (a) Small head<sup>5,7,8,11,13</sup>.
- (b) Soft bristle<sup>5,8,11,13,18</sup>.
- (c) Bristles can be further softened by soaking them in warm/hot water<sup>10,13</sup>.
- (d) In patients with severe microstomia, short bristles are indicated to access occlusal surfaces of molars. For this purpose, bristles can be cut.
- (e) Parents or caregivers are advised to assist children, to improve plaque removal, and helping to reduce the risk of tissue damage<sup>7</sup>.

### Professional hygiene

- D** Gentle and careful ultrasonic scaler and polish techniques can be used in all patients, including severe RDEB<sup>11</sup>.

### Fluoride

- D** Topical applications of high-dose fluoride varnish are suggested every 3 months in patients with high caries risk or at each dental visit<sup>5,7,19</sup>.
- D** For children resident in nonfluoridated communities, the importance of daily fluoride supplements has been highlighted<sup>10</sup>.

### Dietary modifications

- D** A dietary caries-prevention programme should be instigated at early age<sup>16,18</sup>.
- It is essential that dentists and nutritionists collaborate on an appropriate programme for each patient, as opposed to giving contradictory advice that may confuse patients and parents/guardians.

### Microstomia

- Patients with severe generalized RDEB should perform daily exercises to improve/maintain a good mouth opening. This can be performed, for example, during dressing changes.

### Prescriptions.

- When prescribing drugs to patients with RDEB, it is important to consider that they often present oesophageal stenosis. Therefore, prescriptions should be in liquid form, that is, soluble painkillers (analgesics), ideally a sugar-free form.

### Review appointments.

- D** Frequency of dental review should be scheduled according to the risk of caries every 3 to 6 months<sup>5,15,22,27</sup>.
- D** As the predisposition to develop intra-oral carcinoma (SSC) increases with age, cancer screening must be considered a very important aspect of the review appointment in patients with RDEB from the second decade on<sup>19,28</sup>.

### Treatment modifications – precautions

#### EB simplex (EBS).

- D** Routine dental treatment can be provided<sup>5,22,29</sup>.

#### Junctional EB (JEB).

- D** Dental management does not require many modifications<sup>4</sup>; however, a careful



approach is advised as tissue manipulation can produce oral ulceration.

- This group of patients requires an aggressive preventive programme and frequent visits to the dentist as they present enamel hypoplasia/defects, leading to an increased risk for cavities and severe attrition.

#### *Dominant DEB (DDEB).*

- D** Patients with DDEB are able to receive routine dental treatment with little or no modifications<sup>28</sup>.

#### *Recessive DEB (RDEB).*

Patients with the severe generalized RDEB subtype of EB require several treatment modifications and a careful approach to avoid as much tissue damage as possible. Management of these patients ideally requires a well-organized multidisciplinary team approach<sup>27,30</sup> with good communication involving case discussion.

#### 1. Lubrication

- D** Lips should always be lubricated with Vaseline®/petrolatum or other appropriate lubricant before any procedure is performed to reduce adherence and lesions formation<sup>1,5,18,27,31</sup>.

#### 2. Suction tip

- Bullae formation or epithelium sloughing can occur upon contact with the suction tip<sup>1</sup>. It is suggested to lean the suction tip or saliva ejector upon hard tissue, that is, on the tooth surface. High vacuum suction should be avoided.

#### 3. Bullae

- D** Blood- or fluid-filled bullae that occur during treatment have to be drained with a sterile needle or by a cut with scissors to avoid lesion expansion because of fluid pressure<sup>13,22,23,33</sup>.

#### 4. Pressure

- D** Extreme care of fragile tissues is important. To handle tissues, a little pressure (compressive forces) can be applied, but no sliding movements (lateral traction or other shear forces) should be used, as these can cause tissue sloughing<sup>5,11,23</sup>.

#### 5. End of session

- At the end of every clinical session, it is important to check for fluid-filled blisters and drain them. It is also important to check whether there are remnants of dental materials.

#### *Kindler syndrome*

- D** A careful approach is advised, as mucosal sloughing can form following dental treatment<sup>34</sup>.

#### *Dental radiographs.*

- In patients with severe generalized RDEB, periapical technique is difficult in the posterior area because of microstomia, ankyloglossia, and scarring of the sublingual area. Orthopantomography (panoramic) is the investigation of choice. Other alternatives are as follows: small films bitewings, extraoral bitewings capabilities in panoramic radiographs (if equipment is available), and occlusal or lateral oblique techniques.

#### *Restorations.*

- D** There are no contraindications to the use of conventional dental materials<sup>5,38</sup>.
- D** Restorations and dentures should be carefully adapted and highly polished to lessen the risk of iatrogenic oral mucosal blisters and ulcers<sup>18</sup>.

#### *Endodontics.*

- D** Root canal treatment (endodontic treatment) can be performed in all patients, unless there is no access because of limited mouth opening<sup>32</sup>.

#### *Oral rehabilitation.*

- Whenever possible, fixed rehabilitation is advised.
- In cases with generalized enamel hypoplasia, restoration of the entire dentition with full crowns may be necessary.

*Suturing.*

- Sutures can be used safely in all patients with EB, but need careful placement.

*Surgical extractions.*

- D** When planning surgical extractions, especially if multiple extractions are needed, it is advisable to consult the patient's physician as profound anaemia could complicate the dental surgery<sup>30</sup>.

*Osseointegrated implants.*

- To avoid destruction of the atrophic residual alveolar ridges of the maxilla, an osteotome technique is advised<sup>23,31</sup>.

*Orthodontics.*

- For patients with RDEB, we strongly recommend serial extractions to prevent dental crowding, as this contributes to high caries risk and periodontal disease.

*Anaesthetic management*

All kinds of dental treatment for patients with EB can be provided under local anaesthesia,

conscious sedation, or general anaesthesia. The decision on which type of analgesia to choose will have to be agreed between the patient and the dentist based on the advantages and disadvantages of each technique, as well as the availability of specialized services. It is important to highlight that conscious sedation should not be performed in-office on patients with potential for compromised airway or difficult intubation.

*Local anaesthesia.*

- D** To avoid blister formation, the anaesthetic solution should be injected deeply into the tissues and at a slow rate, to avoid the liquid causing mechanical separation of the tissue<sup>5,23,31</sup>.

*General anaesthesia.*

- D** When planning a procedure under general anaesthesia, the patient's MD/GP should be consulted<sup>13</sup>.
- The availability of an anaesthetic team with experience in EB is crucial. If this is not available, the use of local anaesthesia should be considered.

## 6 Development of the guideline

### 6.1 The guideline development group

#### 6.1.1 Clinical Experts.

Prof. Dr. Susanne Krämer	Department of Paediatric Dentistry, Facultad de Odontología, Universidad de Chile Oral Medicine and Special Care Dentistry Unit, UCL Eastman Dental Institute, London, UK Dentist, DEBRA Chile
Dr. María Concepción Serrano	Private practice, Valencia, Spain
Prof. Dr. Gisela Zillmann	Department of Paediatric Dentistry, Facultad de Odontología, Universidad de Chile Dentist, DEBRA Chile
Dr. Pablo Gálvez	Dentist, DEBRA Chile

#### 6.1.2 Patient Representatives.

Mr. John Dart	Chief Operating Officer, DEBRA International, UK
Mr. Scott O'Sullivan	Patient representative, UK

#### 6.1.3 Methodologists.

Prof. Dr. Julio Villanueva	Evidence based Dentistry Unit, Facultad de Odontología, Universidad de Chile
Dr. Ignacio Araya	Evidence based Dentistry Unit, Facultad de Odontología, Universidad de Chile
Dr. Alonso Carrasco-Labra	Evidence based Dentistry Unit, Facultad de Odontología, Universidad de Chile
Dr. Romina Brignardello-Petersen	Evidence based Dentistry Unit, Facultad de Odontología, Universidad de Chile
Mr. Patricio Oliva	PhD candidate in Public Health and Biomedical Research Methods, Universitat Autònoma de Barcelona, Barcelona, Spain.
Dr. Nicolás Yanine	Evidence based Dentistry Unit, Facultad de Odontología, Universidad de Chile
Prof. Dr. Marco Cornejo	Evidence based Dentistry Unit, Facultad de Odontología, Universidad de Chile

### 6.2 Funding for Guide Development

The guideline was funded by a grant from DEBRA UK.

### 6.3 Updating Procedure

The guideline will be updated every two years after its first version. If new relevant evidence is detected before the update, the information will be published on the web site <http://www.debra-international.org/>.

The team in charge of this update will be formed by Dr. Susanne Krämer and Dr. Julio Villanueva in 2013

### 6.4 Methodology

#### 6.4.1 Systematic Literature Searching. Literature Sources

The literature search ranged from 1970 to November 2010. Consulted sources included the electronic databases MEDLINE (1970 to November 2010), EMBASE (1980 to November 2010), CINAHL (1980 to November 2010),

The Cochrane Library (2010), DARE (2010), and the Cochrane controlled trials register (CENTRAL) (2010). In addition, hand-searching journals, reviewing conference proceedings, and other guidelines sources such as The US National Guideline Clearinghouse and The German Guidelines Clearinghouse were carried out.

Dissertations, conference proceedings, technical reports, and other unpublished documents that meet the selection criteria were also included. The reference lists of all papers for relevant citations were reviewed. When all the relevant studies were identified, they were sent to the experts to review for completeness.

Selection criteria of the articles – Primary or secondary articles in which the main topic is dental care (diagnosis, and/or treatment and/or prognosis) in patients with epidermolysis bullosa, published between 1970 and 2010 in English, Spanish, French, German, or Italian were considered.

Search strategy – To identify studies for this review, detailed search strategies were

developed for each database. These were based on the search strategy developed for MEDLINE, but revised appropriately for each database.

The search strategy used a combination of controlled vocabulary and free text terms based on:

- #1 (Epidermolysis Bullosa):ti, ab, kw
- #2 MeSH descriptor epidermolysis bullosa explode all trees
- #3 (Dentistry): ti, ab, kw
- #4 MeSH descriptor Oral Health explode all trees
- #5 (Mouth Disease MeSH term)
- #6 (Mouth Disease): ti, ab, kw
- #7 (Mouth Rehabilitation MeSH term)
- #8 (#1 AND #3)
- #9 (#2 OR #3)
- #10 (#1 AND #4)
- #11 (#1 AND #5)
- #12 (#2 AND (#5 OR #7))
- #13 (#1 AND (#4 OR #6 OR #7))
- #14 (#8 AND #6)

With the aim of seeking specifically for randomized controlled trials and epidermolysis bullosa, the search terms described above were combined with the following terms:

- 1) Randomized controlled trial.pt.
- 2) Controlled clinical trial.pt.
- 3) Randomized controlled trials.sh.
- 4) Random allocation.sh.
- 5) Double-blind method.sh.
- 6) Single-blind method.sh.
- 7) or/1–6
- 8) Animal/not human/
- 9) 7 not 8
- 10) Clinical trial.pt.
- 11) exp clinical trials/

12) (clin\$ adj25 trial\$).ti,ab.

13) [(singl\$ or doubl\$ or trebl\$ or tripl\$) adj25 (blind\$ or mask\$)].ti,ab.

*6.4.2 Methods Used for Formulating the Recommendations.* To formulate the recommendations of the selected studies, the SIGN system was used as described on the 50 Guideline Developer's Handbook, NHS Scottish Intercollegiate Guidelines Network SIGN. Revised Edition January 2008 (See figure on page 2 of this guideline).

## 6.5 External Review

*6.5.2 Patient Group.* Patients and representatives from the DEBRA association groups of Australia, Belgium, Canada, Germany, New Zealand, and the United Kingdom were invited to review the document in order to make sure that the degree to which the evidence addresses patients' concerns is reflected in the guideline.

### 6.5.3 Other health care professionals and lay reviewers.

Anne W Lucky, MD	Acting Director, Division of Pediatric dermatology Cincinnati Children's Hospital. Cincinnati, Ohio, USA Professor of Dermatology and Pediatrics The University of Cincinnati College of Medicine Cincinnati, Ohio USA
Lesley Haynes	Formerly Principal Paediatric Dietitian for EB, Great Ormond Street Hospital for Children, London, UK
Lynne Hubbard	Specialist Dietitian, St. Thomas' Hospital, London, UK
Christian Fingerhuth	Lay reviewer, Chile

### 6.5.1 Specialist Review:

Prof. Dr. Tim Wright	Bawden Distinguished Professor and Chair, The Department of Pediatric Dentistry, The University of North Carolina, Chapel Hill, NC USA
Dr. Marie Callen	Private practice, Cincinnati, USA
Dr. Carol Mason	Consultant in Paediatric Dentistry, Great Ormond Street Hospital for Children NHS Trust, London, UK
Prof. Dr. Stephen Porter	Institute Director and Professor of Oral Medicine, UCL Eastman Dental Institute, London, UK
Dr. Nina Skogedal	Specialist in Paediatric Dentistry, National Resource Centre for Oral Health in Rare Medical Conditions (TAKO-centre), Lovisenberg Diakonale Hospital, Oslo, Norway.
Dr. Kari Storhaug	Director dr.odont., National Resource Centre for Oral Health in Rare Medical Conditions (TAKO-centre), Lovisenberg Diakonale Hospital, Oslo, Norway.
Dr. Reinhard Schilke	Department of Conservative Dentistry, Periodontologie und Preventive Dentistry, Hannover Medical School, Germany.

## 6.6 Pilot

The guideline was piloted in three centres for a period of three months. At the end of the pilot period a feedback form was sent to the authors.

Dr. Victoria Clark	Consultant in Paediatric Dentistry, Birmingham Children's Hospital, UK
Dr. Gabriela Scagnet	Dentist, DEBRA Argentina & Universidad de Buenos Aires and Hospital de Odontología Infantil Quinquela Martin Gobierno, Buenos Aires, Argentina
Dr. Mariana Armada	Hospital de Odontología Infantil Quinquela Martin Gobierno, Buenos Aires, Argentina
Dr. Adela Stepanska	Dentist, DEBRA Czech Republic
Dr. Renata Gaillyova	Department of Genetics, University Hospital, Brno, Czech Republic
Dr. Sylvia Stepanska	Practical dentist, Brno, Czech Republic

## 6.7 Patient involvement

One patient, Scott O'Sullivan from England, participated during the consensus meeting held in Santiago, Chile in November 2010 expressing his opinion and experience regarding dental treatment. Patients and representatives from seven DEBRA association groups were invited to review the document in July and August 2011.

## 6.8 Implementation barriers

According to the context of implementation of this guideline, some barriers to be considered are:

- Lack of knowledge and training of some health professionals to implement the recommendations.
- Lack of patient's adherence to the recommendations.
- Insufficient provision of health services in some parts of the world.

## 6.9 Further areas of research:

- A more detailed study on the effect of sucralose.
- To study the relationship between nutritional state (weight) and oral rehabilitation.
- To study which is the best toothbrush for patients with EB.
- To study the usefulness and safety of using chewing gum with polyol sweeteners such as xylitol to reduce caries in patients with EB.
- Techniques to minimize or improve microstomia.
- Techniques to minimize or avoid vestibule obliteration.
- Which is the best technique to treat vestibule obliteration?
- Is atraumatic orthopaedic tooth alignment in patients with RDEB possible?

## 7 Appendix

### 7.1 LIST OF ABBREVIATIONS

#### Abbreviations

EB	Epidermolysis bullosa
EBS	EB simplex
JEB	Junctional EB
DEB	Dystrophic EB
RDEB	Recessive DEB
DDEB	Dominant DEB
RDEB, sev gen	Severe generalized RDEB
SCC	Squamous cell carcinoma

### 7.2 ORAL MANIFESTATIONS OF EB

The frequency and severity of the oral manifestations of EB vary with the type of disease; however, in general, the oral mucosal lesions of EB comprise vesiculobullous lesions that vary from small, discrete vesicles to large bullae. These lesions can be distributed on all of the mucosal surfaces. Differences exist with regard to the prevalence and severity of oral involvement among the different EB types, patients with the generalized RDEB being the most severely affected<sup>19,28</sup>.

The hard tissues also present different involvement depending on the form of EB. Patients with JEB present with generalized enamel hypoplasia, and individuals with RDEB and JEB have significantly more caries when compared with other EB types or unaffected controls, whereas patients with EBS and DDEB do not have an increased caries risk<sup>19</sup>.

#### EB simplex

Although the most recent classification<sup>58</sup> considers two major subtypes and 12 minor subtypes of EBS, most of the literature on the oral aspects of EBS precedes this classification system; hence, the following text will consider the oral manifestations of EBS as a group and will only reflect on the subtype when available.

Oral ulcers. Oral mucosal ulceration was described in 2% of patients with EBS in an

early report. A more recent case series reported greater involvement, although oral mucosal involvement was not always determined by direct clinical examination but by a history of oral ulceration<sup>28</sup>. 40.3% of the group of 124 patients with EBS had oral ulcers with 58.6% of those with generalized and 34.7% with localized EB. Oral mucosal involvement was reported to be more common during the perinatal period, but in some patients, it persisted during early childhood or even later (Image 13)<sup>28</sup>.

**EBS, localized (EBS-loc)** (previously termed EBS Weber-Cockayne)

There is some dispute as to the frequency of oral mucosal lesions in EBS-loc. Whereas Sedano<sup>59</sup> reported this subtype does not give rise to oral mucosal lesions, Wright<sup>28</sup> reported that 34.7% (33/95) of the patient with localized EBS had a history of or presence of oral mucosal blisters at examination.

**EBS, Dowling-Meara (EBS-DM)**

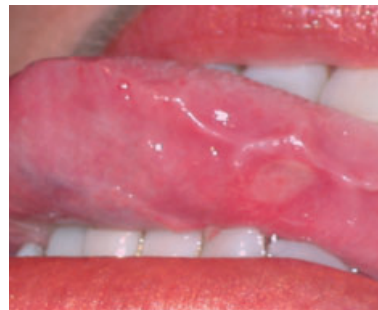37% of one case series of patients with EBS-DM were noted to have intraoral soft tissue damage<sup>5</sup>.

**EBS, other generalized (EBS, gen-non-DM)** (includes patients previously classified as having EBS-Koebner)

A review suggested that this group of patients may have occasional intraoral blisters that are less severe than those of other EB types<sup>59</sup>.

**EBS with muscular dystrophy (EBS-MD)**

Only one report of this uncommon subtype of EBS included details of oral features. The patient had lost her teeth, which had enamel



**Image 13** Ulcer on the lateral border of the tongue in a patient with EBS.

defects, by the age of 16 years. The mucous membranes were normal<sup>60</sup>.

### Junctional EB

Intraoral soft tissue involvement. Major oral mucosal bullae and areas of granulation tissue seem infrequent<sup>5,28</sup>, although a history of and presence of blisters is high (88.8%)<sup>28</sup>. Patients rarely present evidence of severe intraoral scarring<sup>4,19,28</sup>.

Perioral tissue involvement. Perioral and perinasal crusted and granular haemorrhagic lesions, which can involve large areas of the face and cause occlusion of the nostrils, tend to develop between the sixth and twelfth month of life in patients with the Herlitz subtype (Image 14). The lesions were noted in all patients with Herlitz JEB and tended to resolve during or after adolescence in patients who survived (Image 15)<sup>28,59</sup>. They are believed to be pathognomonic for JEB-H<sup>59</sup>.

Microstomia. One case series studied the commissure-to-commissure distance obtaining 39.2 mm in Herlitz JEB, 46.7 mm in non-Herlitz JEB, and 44.7 mm in the healthy controls. Statistically these differences were not significant<sup>28</sup>.

Generalized enamel hypoplasia. Generalized enamel hypoplasia has been reported in 40 individual cases with JEB<sup>4,19,43,53,61-65</sup>, as well as 100% of the patients with JEB in a series of cases ( $n = 6$  JEB-H,  $n = 19$  JEB-O)<sup>66</sup>. Enamel hypoplasia can be observed in panoramic radiographs showing all teeth with

thin, abnormal, severely dystrophic enamel formation (Images 16 and 17)<sup>53</sup>.

The severity of enamel defects varies between teeth and individuals; in one series, 66.7% of the patients demonstrated generalized, rough, pitted enamel hypoplasia, whereas the remaining cases showed generalized thinning and/or furrowing of the enamel<sup>66</sup>.

Herlitz forms of JEB have shown a tendency to have thin ( $\approx 40 \mu\text{m}$ ), prismless enamel<sup>66,67</sup>. Non-Herlitz JEB patients, on the other hand, present a rather thicker but porous enamel with pits. The prismatic structure was normal but interrupted by marked surface pitting<sup>66,67</sup>.

Enamel hypoplasia has been described in patients with JEB caused by mutations in the genes of laminin-332,  $\alpha 6\beta 4$ -integrin, and type XVII collagen<sup>67-72</sup>.

### Failure of eruption

Failure of teeth eruption has been noted in two reports.<sup>4,43</sup>

### **JEB, Herlitz (JEB-H)**

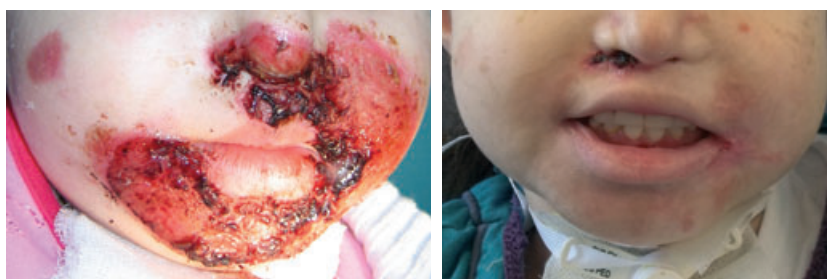Oral lesions, including a history of and/or presence of blisters, were reported in 83.3% of one group of patients with JEB-Herlitz<sup>28</sup>.

### **JEB, other (JEB-O)**

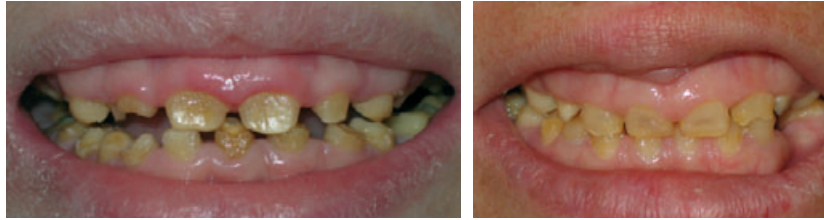Oral lesions, including a history of and/or presence of blisters, were reported in 91.6% of a group of 12 patients<sup>28</sup>.

**JEB, non-Herlitz, localized (JEB-nH loc)** (formerly known as generalized atrophic benign EB GABEB, COL XVII mutation)

Most patients develop blisters and ulcers on the oral mucosa during infancy, which can cause difficulties eating and performing oral



**Images 14 and 15** Area of perioral granulation tissue in a patient with JEB at the age of 2 and the same patient at the age of 9.



Images 16 and 17 Generalized enamel hypoplasia in patients with JEB.

hygiene; but after puberty, the oral mucosal condition tends to ameliorate. Few patients have continuous blister formation on the oral mucous membranes. These blisters heal without scarring<sup>73</sup>.

### Dystrophic EB

*Dominant DEB (DDEB).*

#### Soft tissue involvement

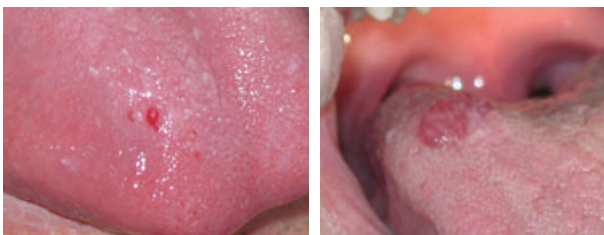There is no agreement about the extent of oral mucosal involvement in DDEB. One review stated that 20% of patients have oral mucosal bullae<sup>59</sup>, although a case series indicated that 71.1–89.6% of patients may have a history of or oral clinical features of oral mucosal blistering (Images 18 and 19)<sup>5,28</sup>. Of note, significant scarring, vestibular obliteration, and ankyloglossia do not seem to be long-term complications of oral mucosal ulceration/blisters<sup>28</sup>.

Hard tissue involvement. Patients with DDEB do not seem to be at increased risk of caries<sup>5,19</sup>.

#### **Recessive DEB (RDEB)**

##### **RDEB inversa (RDEB-I)**

RDEB inversa subtype is an uncommon form of EB. Patients present with mucosal blistering (especially sublingually), ankylo-



Images 18 and 19 Blood-filled bullae on the tongue in patients with DDEB.

glossia, absence of tongue papillae and palatal rugae, partial obliteration of the vestibule, microstomia secondary to scarring, and mucosal milia<sup>5,74,75</sup>. Of note, oesophageal involvement and dysphagia affected 90% of one group of ten patients<sup>74</sup>.

Hard tissue involvement. A significantly higher prevalence of caries (DMFS: 50.9) than the control group (DMFS: 12.8) was reported in a study of ten patients. Enamel abnormalities have only been reported in one of 14 patients having a localized enamel defect of one tooth<sup>74</sup>.

### **Generalized RDEB**

The following text includes all patients with both generalized forms of RDEB ('severe generalized', previously called Hallopeau–Siemens: HS and 'generalized other').

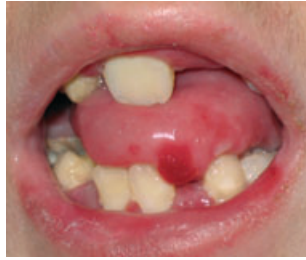Soft tissue involvement. The oral mucosa of patients with generalized RDEB is reported to be extremely friable and may slough off easily when touched<sup>45</sup>. Recurrent oral mucosal blistering is common, affecting almost all patients<sup>9,11,16,22,27,30,36,51,76</sup>. The blisters may be fluid- or blood-filled and arise at any oral mucosal surface, especially the tongue (Images 20–23).<sup>22</sup>

Denuded tongue. Tongue papillae are absent.<sup>4,5,7,9,18,22,28,30,36,41</sup> (Image 24)

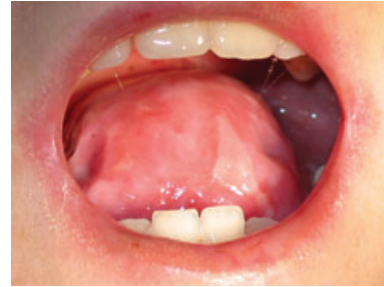Ankyloglossia. Ankyloglossia presumably secondary to ulceration is common, indeed may affect all patients (Image 25)<sup>1,4,5,7,12,16,18,19,22,23,28,31,77</sup>.

Vestibule obliteration. The scarring of generalized RDEB can give rise to obliteration of the

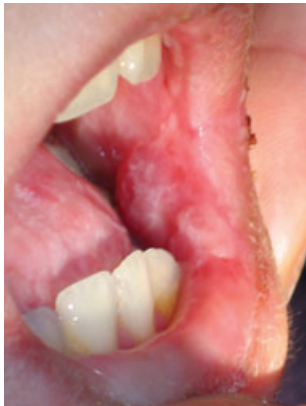



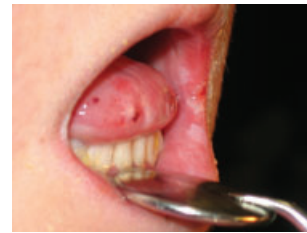**Image 20** Blood-filled bullae on the tongue of a patient with RDEB.



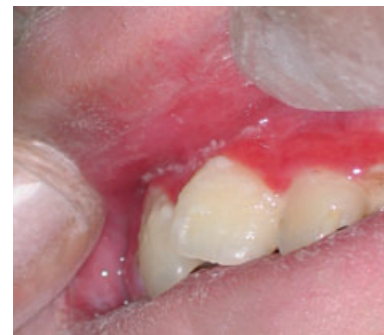**Image 24** Absence of tongue papillae in RDEB.



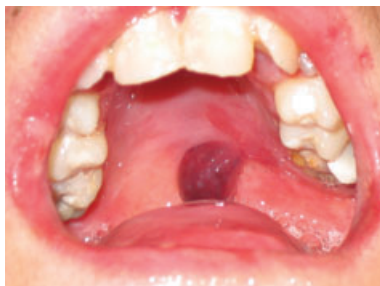**Image 21** Bullae on the buccal mucosa of a patient with RDEB.



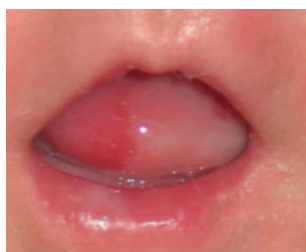**Image 25** Ankyloglossia in RDEB.



**Image 26** Obliteration of the labial vestibule in RDEB.



**Image 22** Blood-filled bullae on the palate of a patient with RDEB.

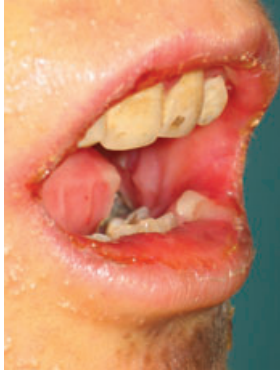

**Image 23** Serosus bullae covering more than half of the tongue of a newborn with RDEB.

labial and buccal vestibules<sup>4,7,9,11,12,18,19,22,23,27,28,31,36,41</sup> and hence has the potential to compromise oral hygiene procedures, dental treatment, and the wearing of removable prosthetic appliances (Image 26).

Microstomia. Progressive<sup>5,78</sup> microstomia affects almost all patients with generalized RDEB (Image 27)<sup>1,4-7,11,12,16,18,19,22,27,28,36,41,45,51,77</sup>. Microstomia is not unique to generalized RDEB, and it might also be present less severely in RDBE inversa and Herlitz subtype of JEB<sup>5,19</sup>. The degree of microstomia of patients with generalized RDEB has been reported to be severe in over 80% of affected individuals<sup>1,7,22,23,31,41,45,51</sup>.

The exact cause of microstomia of generalized RDEB is not known, although it seems



**Image 27** Limited mouth opening in RDEB.

likely that it reflects the scarring of the buccal and labial mucosa and commissures<sup>1,5,9,28</sup>.

The microstomia of generalized RDEB gives rise to a wide variety of functional problems that include difficulties in eating, speech, and oral hygiene maintenance. Additionally, dental treatment and general anaesthesia can be complicated and the aesthetics of the lower face compromised<sup>19,22,25,36,79</sup>.

**Cancer risk.** Squamous cell carcinoma (SCC) has been described as the leading cause of death in patients with EB<sup>80</sup>. Few cases affecting the oral cavity have been reported. The tongue is the most commonly affected site, although tumours on the lip and the hard palate have also been reported. The age of diagnosis has ranged from 25 to 54 years of age. At least three cases have been lethal<sup>5,28,77,81</sup>.

**Periodontal disease.** Extensive plaque deposits have been reported on most patients<sup>4,11,16,27,41,45</sup>. Mean plaque score measured using a modification of the index of O'Leary revealed higher values for patients with DEB ( $n = 23$ ; 18 RDEB, five DDBE) in the primary ( $33.7 \pm 31.3$ ) and secondary dentitions ( $28.6 \pm 31.6$ ) when compared to a

control group ( $1.8 \pm 3.3/4.6 \pm 5.6$ , respectively)<sup>20</sup>.

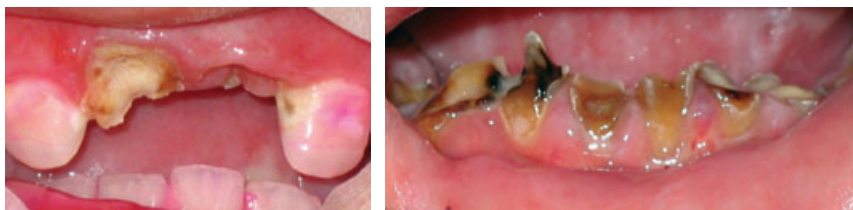Mean gingivitis scores (using the simplified gingival index) have been found to be significantly greater in patients with DEB ( $n = 23$ ; 18 RDEB, five DDBE) in both primary ( $21.5 \pm 29$ ) and permanent dentitions ( $27.5 \pm 34.9$ ) when compared to a control group ( $0.00/2 \pm 4.6$ , respectively)<sup>20</sup>. There does not appear to be an increased risk of periodontal membrane and bone involvement in RDEB<sup>27,36</sup>.

**Caries.** Patients with RDEB have significantly higher caries scores (DMFT, DMFS, combined DMFS with dmfs and combined DMFT with dmft) than control patients (Images 28 and 29)<sup>5,12,19,20</sup>. Only few patients have been reported to have cellulitis secondary to periapical infection.<sup>30</sup>

**Occlusal abnormalities.** A variety of occlusal anomalies have been described in RDEB including increased overjet and overbite<sup>22</sup>, severe crowding<sup>12,22,49</sup>, cross-bite molar relationship<sup>12</sup>, and class II skeletal malocclusion<sup>22,48</sup>. Some of the anomalies may be due to reduced alveolar arches (secondary to growth retardation) and collapse of the dental arches (secondary to soft tissue retardation)<sup>8</sup>. A cephalometric study of 42 patients with RDEB found significantly smaller jaws in these patients<sup>50</sup>, thus adding weight to the suggestion that significant dento-alveolar disproportion and dental crowding are features of RDEB.

**Dental maturity.** Two studies have been published on dental maturity and dental development in patients with RDEB finding no significant delay<sup>82,83</sup>.

**Facial Growth.** The cephalometric analysis of 42 patients with RDEB, seven gen indicated that



**Image 28 and 29** Severe caries in a 12-year-old and a 20-year-old patient with RDEB.

this subtype of EB gives rise to a significantly reduced maxillary length, mandibular length, middle facial height, and lower facial height when compared to the published normal values. Saddle and nasolabial angles are significantly greater in RDEB than normal<sup>50</sup>. The changes in facial skeleton may reflect reduced nutritional intake (feeding problems) and subsequent reduced bone growth<sup>50</sup>. Additionally, or alternatively, perioral soft tissue scarring during early childhood may result in reduced size of the jaws<sup>84</sup>.

Bone atrophy/osteoporosis. Osteoporosis has been increasingly identified in patients with this form of RDEB in recent years<sup>56</sup>. Radiographic records and computerized tomography scans of the jaw revealed extensive bone atrophy of the jaws in six of six patients<sup>31</sup>. During surgery, the alveolar ridges of these patients were found to be atrophic in all cases<sup>23,31</sup>.

### Kindler Syndrome

Kindler syndrome has only recently been added as part of the classification of EB<sup>58</sup>. Only few case reports of patients with Kindler syndrome describe their oral features<sup>34,85–90</sup>.

The evidence suggests that patients with Kindler syndrome can present with fragile mucosa, microstomia, and partial vestibule obliteration, although microstomia was not identified in all patients with Kindler syndrome<sup>34,85,86</sup>. Special attention has been given to periodontal disease, which was initially reported in two patients<sup>34,88</sup>. Thereafter, a series of 18 patients was compared to healthy controls, revealing that patients with Kindler syndrome have a higher prevalence (72% vs 46%), earlier onset, and faster progression of periodontitis<sup>85</sup>. Squamous cell carcinoma of the hard palate has also been reported in a patient with this condition<sup>86</sup>.

## 7.3 GENERAL INFORMATION ON EPIDERMOLYSIS BULLOSA

Inherited epidermolysis bullosa (EB) comprises a group of genetically and clinically heterogeneous diseases characterized by the

formation of blisters and erosions on skin and mucous membranes following minor traction or trauma<sup>26</sup>. It is caused by mutations in the genes encoding proteins of the dermal–epidermal adhesion zone<sup>91</sup>.

*7.3.1 Classification of EB.* EB presents a wide range of clinical phenotypes with over 1000 mutations identified in 13 structural genes. Classification schemes were first introduced by Pearson in 1962<sup>92</sup>. Since then, various consensus classifications have been published<sup>58,93,94</sup>.

The current classification scheme begins with the separation of EB into four major types based on the level of blister formation into EB simplex (EBS, intra-epidermal), junctional EB (JEB), dystrophic EB (DEB, dermolytic), and Kindler syndrome (mixed levels). Patients are then separated by major and minor EB subtypes. The expanded classification scheme includes the following: four types, seven major subtypes, and 33 minor subtypes<sup>58</sup>. A summary of this classification system is presented in Table 1.

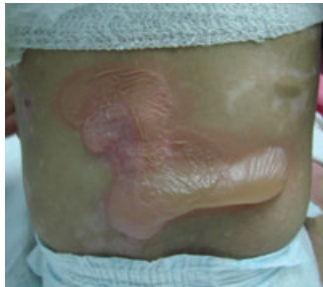*7.3.2 General clinical manifestations.* The hallmark feature of inherited EB is mechanical fragility of the skin and the appearance of vesicles and bullae<sup>36</sup>. In most forms of EB, tense blisters form with clear, colourless exudate or occasionally haemorrhagic fluid, eventually giving rise to eroded areas<sup>26</sup>. The blisters and erosions can occur as a result of trauma but may also arise spontaneously<sup>36</sup> and can be exacerbated by sweating and warmer climates<sup>33</sup>. Other findings include milia, dystrophy, or absence of nails, alopecia, exuberant granulation tissue, congenital absence of skin, palmoplantar keratoderma, mottled pigmentation, and pigmented naevi<sup>26</sup>.

Secondary skin lesions are cutaneous atrophy, scarring, pigmentary abnormalities, webbing and contractures (Images 30–32)<sup>26</sup>.

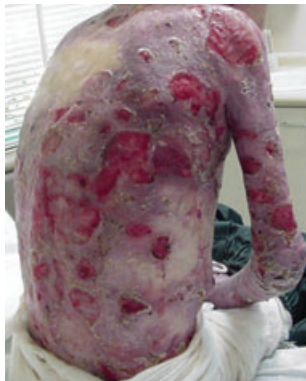*EB and cutaneous squamous cell carcinoma:* Squamous cell carcinoma (SCC) of the skin is one of the most severe complications of EB, starting to arise in early adulthood in patients with the severe forms of EB, notably RDEB. SCC can present as a nonhealing, crusted ero-

**Table 1. Simplified classification scheme of the EB spectrum.**

Major EB types	Major subtypes	Target protein	Minor subtypes
EB simplex (EBS)	Suprabasal EBS	Plakophilin-1 desmoplakin	3 subtypes
	Basal EBS	Keratin 5 and 14 plectin integrin $\alpha 4\beta 6$	9 subtypes
Junctional EB (JEB)	JEB-Herlitz	Laminin 332	–
	JEB, other	Laminin 332 type XVII collagen integrin $\alpha 4\beta 6$	6 subtypes
Dystrophic EB (DEB)	Dominant DEB	Type VII collagen	6 subtypes
	Recessive DEB	Type VII collagen	7 subtypes
Kindler syndrome	–	Kindlin-1	–



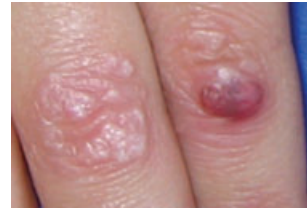**Image 30** Extensive bullae covering the back of a patient with RDEB.



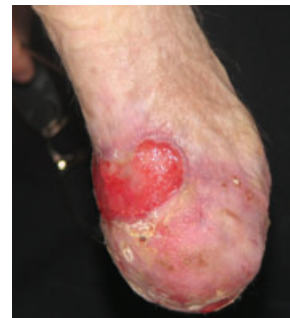**Image 31** Ulceration and scarring in JEB.

sion with little or no palpable dermal component, similar to other wounds on the skin, or mimic areas of granulation tissue<sup>26</sup> (Image 33).

*Ocular findings in EB:* The most common ocular findings in patients with EB include corneal blisters and erosions, corneal scarring, pannus formation, limbal broadening, con-



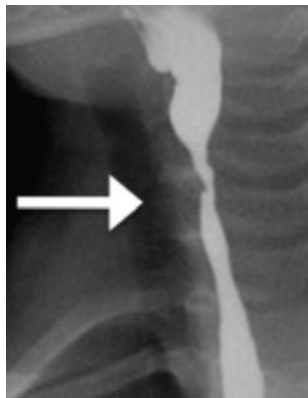
**Image 32** Blister in EBS.



**Image 33** Squamous cell carcinoma in RDEB.

junctival blisters and erosions, symblepharon, eyelid blisters and scars, ectropion, and lacrimal duct obstruction. Marked visual impairment can result from repeated injury to the cornea, especially if scarring develops<sup>26</sup>.

*Ear, nose, and throat in EB:* Signs and symptoms in the upper respiratory tract in patients with EB can include weak or hoarse cry, dysphonia, inspiratory stridor, soft tissue oedema, vesiculation or blistering of all tracheolaryngeal structures and ulceration, thickening and scarring of the true and false vocal cords<sup>26</sup>.



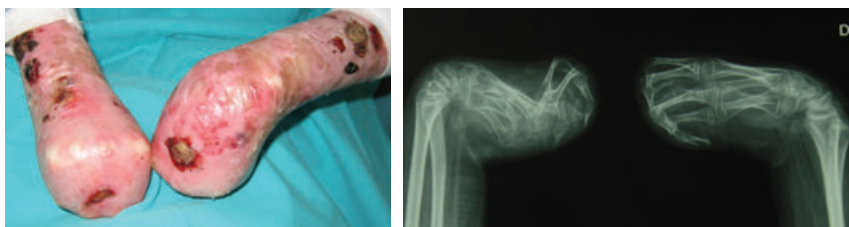**Image 34** Severe oesophageal stenosis in a patient with RDEB.

*Dysphagia and oesophageal strictures:* EB-associated strictures may arise anywhere in the oesophagus and vary in length and shape (Image 34). Over time, intra-luminal bullae, web formation, and strictures result in progressive dysphagia with all its consequences, including severe malnutrition, growth impairment, and the risk of aspiration and pneumonia. Dysphagia can present as early as 10 months, with an average of onset at  $48 \pm 34$  months<sup>95</sup>.

*Lower gastrointestinal tract complications:* The most common lower gastrointestinal complaint is chronic constipation in patients with the more severe EB subtypes<sup>26</sup>.

*Malnutrition:* Nutritional compromise is directly proportional to the severity of EB and occurs mainly in generalized form of recessive dystrophic EB (RDEB) and junctional EB<sup>96–98</sup>.

*Acral deformities:* Pseudosyndactyly is the most visible extracutaneous complication of inherited EB and is primarily seen in RDEB. These progressive deformities can cause marked functional disability (Images 35 and 36)<sup>26</sup>.



**Image 35 and 36** Mitten deformities in RDEB.

*Anaemia:* Anaemia occurs in patients with severe EB, particularly RDEB-HS and JEB-H. In most patients, the anaemia is multifactorial in origin. Contributing factors include chronic blood, iron, and protein loss from open wounds on the skin and poor intake and gastrointestinal absorption of iron and other nutrients<sup>26</sup>.

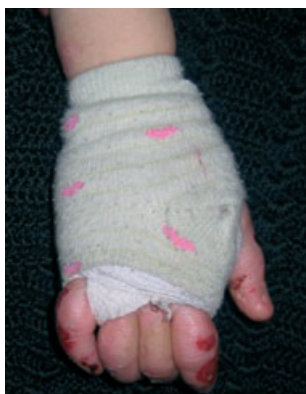*Cardiomyopathy:* Dilated cardiomyopathy was reported in 9.8% of a series of 61 patients with RDEB with a mean age of confirmation of diagnosis of 8.7 years<sup>99</sup>.

*Osteoporosis and osteopenia:* A study of 39 children indicated that patients with RDEB and JEB had lower bone mineral density scores than control children<sup>56</sup>. In this study, a correlation was noted between low bone mass and reduced body mobility.

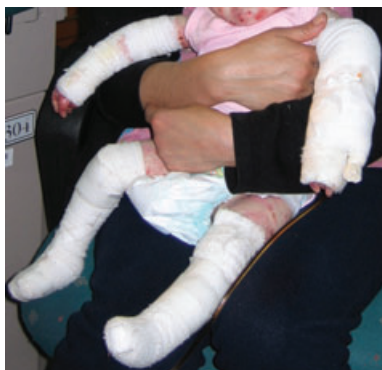**7.3.3 Management.** A systematic review of randomized controlled trials of treatments for inherited forms of EB was published in 2008<sup>100</sup>. Up to the 1 April 2007, the researchers identified five randomized double-blind placebo-controlled crossover trials. None of the studies showed a benefit of the intervention over placebo<sup>100</sup>.

There is still no reliable trial evidence for interventions in inherited EB. Gene, protein, and cell therapies are being researched, but until reliable evidence becomes available, most treatment of EB is directed towards preventative, supportive, symptomatic, and palliative goals.

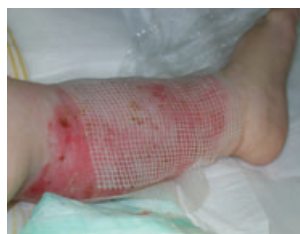*Prevention of blisters:* Protection of the fragile skin of EB is of utmost importance (Images 37–38). A cool environment and skin lubrication can help lessen blister formation. Sheepskin is used for padding car seats, infant seats, and other surfaces. Young children



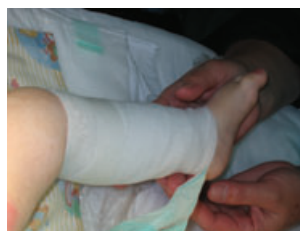**Image 37** Hand wrapping to prevent webbing.



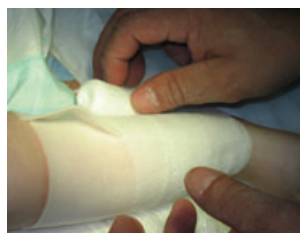**Image 38** Bandages on the four limbs to prevent trauma.



**Image 39** Primary bandage.



**Image 40** Secondary bandage to absorb humidity.



**Image 41** Gauze wrap to keep bandages in place.

should not be picked up under the arms, but be lifted from the bottom and the back of the neck. Clothing should be made of soft fabric and simple design<sup>26</sup>.

*Management of EB wounds:* Most EB wound care techniques consist of multiple layers of bandages or sterile nonadherent materials (Images 38–40). Dressings are changed on a daily basis or every second day. Blisters must be drained, ideally under sterile conditions, to prevent them enlarging and giving rise to larger erosions<sup>33</sup>.

Dressings should aim to maintain appropriate moisture, be nonadherent, atraumatic, promote a healthy wound bed, reduce pain, and increase speed of re-epithelialization.

*Surgical interventions:* Patients with EB, especially RDEB, often require surgery within the oral cavity, gastrointestinal tract, and on the hands. Among the challenges for anaes-

thesiologists are microstomia, ankyloglossia, intraoral blistering, and sloughing, and the possible need for tracheostomy. When procedures under general anaesthesia are planned, it is best to coordinate as many interventions as possible to avoid repeated anaesthesia<sup>26</sup>.

*Anaesthetic management<sup>C</sup>:* Anaesthetic management of patients with EB presents several difficulties as a result of mucosal fragility, severe scarring of all tissues, and oesophageal strictures increasing the risk of regurgitation and aspiration during anaesthesia. Coordinated care with dermatologists, surgeons, and

<sup>C</sup>The present document is not a systematic review neither a guideline on anaesthetic management in EB. The list of special considerations during general anaesthesia is a result of a nonsystematic literature review aimed only at giving the dentist an insight on the precautions during surgery.

**Table 2. Anaesthetic management special considerations in epidermolysis bullosa.**

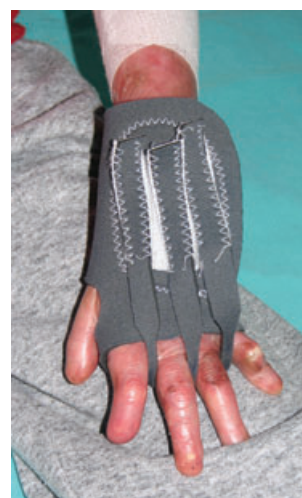Anaesthetic management considerations	
General	No adhesive of any type should be used <sup>30,57</sup> Pressure points should be protected with Vaseline or soft gauze <sup>101</sup>
Patient positioning and moving	Patients should place themselves on the operating table if possible <sup>101</sup> Stretcher should be padded with sheepskin or a wool blanket <sup>1,30,57</sup> Transfer and position changing should be performed by moving the sheepskin or blanket, not by lifting the patient <sup>57</sup>
Tourniquet	Placed over a gauze wrapped around the extremity or minimal manual occlusion with lubricated hands <sup>57,101</sup>
Intravenous line securing	Vaseline gauze between skin and intravenous hub and securely wrapped with self-adherent, nonadhesive elastic bandages around the extremity. <sup>1,30,57,101</sup> Wrist can be secured using a foam-padded wrist support board <sup>1</sup>
Instrument preparation	Facemask, endotracheal tube, and nasal cannula need to be well lubricated. Contact surfaces need to be covered with several layers of Vaseline gauze or Mepilex <sup>®41,57,101</sup>
Airway management	For safely maintaining an airway, further bullae must be avoided <sup>101</sup>
Surgical site	Should not be scrubbed vigorously, and disinfection solutions should be poured on or gently dabbed on the skin <sup>57</sup>
Monitoring	Clip-type is the pulse oximetry appliance of choice. Other techniques include standard disposable finger/toe probe with the adhesive part cut-off and wrapped with gauze <sup>1,57</sup> For the electrocardiogram, the adhesive part can be cut-off, allowing only the lubricated central portion to contact the patient's skin <sup>1,57</sup> and this can be secured with nonadhesive dressings such as Mepilex <sup>®41</sup> Noninvasive blood pressure cuff should be applied over an extremity wrapped with bandages or cotton <sup>1,57,101</sup>
Complications	In a review of 121 surgical procedures, no death or other major perioperative anaesthetic complication occurred. <sup>57</sup> Fatal oesophageal perforations have been noted twice in previous case series <sup>101</sup> Most common post-operative complication is the development of new blisters. <sup>57</sup> Significant injury after poor handling can occur when inexperienced members of the team are not aware of the risks of handling patients with EB, for example, inadvertent taping of the eyelid <sup>101</sup> Fibre optic tracheal intubation can be required in severe cases because of limited mouth opening and contractures of the neck <sup>57</sup> Maxillary alveolar process fracture secondary to laryngoscopy was reported in a patient with severe generalized RDEB with poor bone health, severe microstomia, and prominent upper incisors <sup>25</sup>

nurses is essential for anaesthesia and perioperative management in patients with RDEB (Table 2).<sup>57</sup>

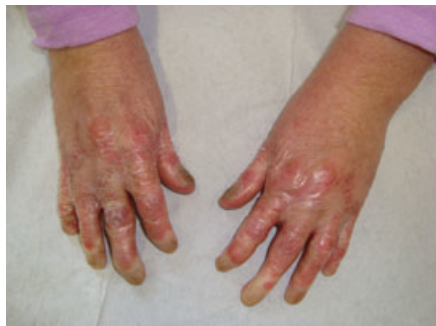*Musculoskeletal complications – hand surgery:*  
**Nonsurgical interventions** – It is a common practice to mechanically separate the digits with gauze wraps on a daily basis in an attempt to prevent, minimize, or delay the EB-associated pseudosyndactyly. Passive and active range exercises are also encouraged (Image 42)<sup>26</sup>.

**Surgical interventions** – A number of surgical interventions have been described. Post-operative recurrence, however, is common and procedures need to be repeated about every 2 years if optimal function is to be maintained (Image 43)<sup>26</sup>.

*Nutritional support:* Proactive nutritional support aids resistance to infection, growth and sexual maturation, wound healing, and over-

**Image 42** Splint to prevent webbing in RDEB.

all quality of life. Adequate energy intake may be unachievable without the frequent consumption of fermentable carbohydrates, especially sucrose. Unfortunately, this is a risk factor for caries. It is thus important that



**Image 43** Post-operative results of hand surgery in a patient with RDEB.

dietitians and dentists work as part of the multidisciplinary team, giving sensible advice to limit consumption of sweets to the end of meals, discouraging sipping of sugary drinks between meals, and giving appropriate advice regarding the prescribing for fluoride supplements and chlorhexidine<sup>98</sup>.

**7.3.4 Quality of life in EB.** A qualitative study with semi-structured interviews published by Scheppingen and co-workers<sup>102</sup> found following as the main areas children with EB experienced problems:

- 1) Having an itchy skin. This was the most frustrating problem in patients with the severe types, entailing a physical, psychological, and social burden.
- 2) Being in pain. There were three main aspects of pain: (1) pain related to treatments such as changing dressings, (2) activity-related pain: that is, eating or walking, and (3) experience of pain is the fear of having pain, which can be a substantial problem in all cases.
- 3) Having difficulties with participation/joining others.
- 4) The visibility of the disease: being teased/stared at and concerns about appearance.
- 5) The feeling of being different, lack of understanding by others.

A Quality of Life Questionnaire specific for patients with EB (QOLEB) was developed by Frew *et al.*<sup>103</sup> The questionnaire contains 17 items and has proved to be a valid and reliable measurement tool. It can be used to monitor quality of life and to identify dimensions of QOL as targets for interventions and research.

## Acknowledgments

The authors would like to thank Dr. Victoria Clark, Dr. Gabriela Scagnet, Dr. Mariana Armada, Dr. Adela Stepanska, Dr. Renata Gaillyova, Dr. Sylvia Stepanska, Mr. John Dart, Mr. Scott O Sullivan, Dr. David Peñarrocha, Prof. Dr. Tim Wright, Dr. Marie Callen, Dr. Carol Mason, Prof. Dr. Stephen Porter, Dr. Nina Skogedal, Dr. Kari Storhaug, Dr. Reinhard Schilke, Prof. Dr. Marco Cornejo, Dr. Anne W Lucky, Lesley Haynes, Lynne Hubbard, Isabel López and Christian Fingerhuth for their contribution to these guidelines, as it has been detailed on chapter 6. This work was funded by a grant from DEBRA UK.

## Conflict of Interests

None of the authors declared conflict of interest.

## References

- 1 Stavropoulos F, Abramowicz S. Management of the oral surgery patient diagnosed with epidermolysis bullosa: report of 3 cases and review of the literature. *J Oral Maxillofac Surg* 2008; **66**: 554–559.
- 2 Skogedal N, Saltnes S, Storhaug K. Recessive dystrophic epidermolysis bullosa (RDEB) Caries prevention and preventive extractions of molars. Clinical presentation of 3 cases. 2008.
- 3 Louloudiadis AK, Louloudiadis KA. Case report: Dystrophic Epidermolysis Bullosa: dental management and oral health promotion. *Eur Arch Paediatr Dent* 2009; **10**: 42–45.
- 4 Crawford EG Jr, Burkes EJ Jr, Briggaman RA. Hereditary epidermolysis bullosa: oral manifestations and dental therapy. *Oral Surg Oral Med Oral Pathol* 1976; **42**: 490–500.
- 5 Wright JT. Oral Manifestations of Epidermolysis Bullosa. In: *Epidermolysis Bullosa. Clinical, Epidemiologic, and Laboratory Advances and the Findings of the National Epidermolysis Bullosa Registry*. edited by: Jo-David Fine, Eugene A. Bauer, Joseph McGuire and Alan Moshell. Baltimore, MD: The Johns Hopkins University Press, 1999: 236–256.
- 6 Finke C, Haas N, Czarnetzki BM. [Value of dental treatment in interdisciplinary management of a child with epidermolysis bullosa dystrophica hereditaria (Hallopeau-Siemens)]. *Hautarzt* 1996; **47**: 307–310.
- 7 Azrak B, Kaevel K, Hofmann L, Gleissner C, Willershausen B. Dystrophic epidermolysis bullosa: oral findings and problems. *Spec Care Dentist* 2006; **26**: 111–115.



- 8 Wright JT, Fine JD, Johnson L. Hereditary epidermolysis bullosa: oral manifestations and dental management. *Pediatr Dent* 1993; **15**: 242–248.
- 9 Boyer HE, Owens RH. Epidermolysis bullosa: a rare disease of dental interest. Review of the literature and report of a case. *Oral Surg Oral Med Oral Pathol* 1961; **14**: 1170–1177.
- 10 Nowak AJ. Oropharyngeal lesions and their management in epidermolysis bullosa. *Arch Dermatol* 1988; **124**: 742–745.
- 11 Olsen CB, Bourke LF. Recessive dystrophic epidermolysis bullosa. Two case reports with 20-year follow-up. *Aust Dent J* 1997; **42**: 1–7.
- 12 De Benedittis M, Petrucci M, Favia G, Serpico R. Oro-dental manifestations in Hallopeau-Siemens-type recessive dystrophic epidermolysis bullosa. *Clin Exp Dermatol* 2004; **29**: 128–132.
- 13 Lozada-Nur F, Kopick M, Mendez M, McGuirre J, Ortega E. Guidelines for patients with oral epidermolysis bullosa (EB): dental and oral care. 1997.
- 14 Cagirankaya LB, Hatipoglu MG, Hatipoglu H. Localized epidermolysis bullosa simplex with generalized enamel hypoplasia in a child. *Pediatr Dermatol* 2006; **23**: 167–168.
- 15 Momeni A, Pieper K. Junctional epidermolysis bullosa: a case report. *Int J Paediatr Dent* 2005; **15**: 146–150.
- 16 Silva LC, Cruz RA, Abou-Id LR, Brini LN, Moreira LS. Clinical evaluation of patients with epidermolysis bullosa: review of the literature and case reports. *Spec Care Dentist* 2004; **24**: 22–27.
- 17 Marini I, Vecchiet F. Sucralfate: a help during oral management in patients with epidermolysis bullosa. *J Periodontol* 2001; **72**: 691–695.
- 18 Siqueira MA, Siqueira MA, de Souza Silva J, Silva FW, Díaz-Serrano KV, Freitas AC, Queiroz AM *et al.* Dental treatment in a patient with epidermolysis bullosa. *Spec Care Dentist* 2008; **28**: 92–95.
- 19 Wright JT, Fine JD, Johnson L. Dental caries risk in hereditary epidermolysis bullosa. *Pediatr Dent* 1994; **16**: 427–432.
- 20 Harris JC, Bryan RA, Lucas VS, Roberts GJ. Dental disease and caries related microflora in children with dystrophic epidermolysis bullosa. *Pediatr Dent* 2001; **23**: 438–443.
- 21 Oliveira TM, Sakai VT, Candido LA, Silva SM, Machado MA. Clinical management for epidermolysis bullosa dystrophica. *J Appl Oral Sci* 2008; **16**: 81–85.
- 22 Serrano C, Silvestre FJ, Bagan JV, Penarrocha M, Alió JJ. Epidermolysis ampollosa hereditaria: a propósito del manejo odontológico de tres casos clínicos. *Medicina Oral* 2001; **6**: 48–56.
- 23 Penarrocha-Diago M, Serrano C, Sanchis JM, Silvestre FJ, Bagan JV. Placement of endosseous implants in patients with oral epidermolysis bullosa. *Oral Surg Oral Med Oral Pathol Oral Radiol Endod* 2000; **90**: 587–590.
- 24 Oliveira MA, Ortega KL, Martins FM, Maluf PS, Magalhaes MG. Recessive dystrophic epidermolysis bullosa – oral rehabilitation using stereolithography and immediate endosseous implants. *Spec Care Dentist* 2010; **30**: 23–26.
- 25 George M, Martinez AE, Mellerio JE, Nandi R. Maxillary alveolar process fracture complicating intubation in a patient with epidermolysis bullosa. *Paediatr Anaesth* 2009; **19**: 706–707.
- 26 Lanschützer C *et al.* *Life with Epidermolysis Bullosa (EB): Etiology, Diagnosis, Multidisciplinary Care and Therapy*. Springer Wien 2009; Springer, 2008.
- 27 Harel-Raviv M, Bernier S, Raviv E, Gornitsky M. Oral epidermolysis bullosa in adults. *Spec Care Dentist* 1995; **15**: 144–148.
- 28 Wright JT, Fine JD, Johnson LB. Oral soft tissues in hereditary epidermolysis bullosa. *Oral Surg Oral Med Oral Pathol* 1991; **71**: 440–446.
- 29 Hochberg MS, Vazquez-Santiago IA, Sher M. Epidermolysis bullosa. A case report. *Oral Surg Oral Med Oral Pathol* 1993; **75**: 54–57.
- 30 Album MM *et al.* Epidermolysis bullosa dystrophica polydysplastica. A case of anesthetic management in oral surgery. *Oral Surg Oral Med Oral Pathol* 1977; **43**: 859–872.
- 31 Penarrocha M *et al.* Restoration with implants in patients with recessive dystrophic epidermolysis bullosa and patient satisfaction with the implant-supported superstructure. *Int J Oral Maxillofac Implants* 2007; **22**: 651–655.
- 32 Kramer SM. Oral care and dental management for patients with epidermolysis bullosa. *Dermatol Clin* 2010; **28**: 303–309.
- 33 Schaffer SR. Head and neck manifestations of epidermolysis bullosa. *Clin Pediatr (Phila)* 1992; **31**: 81–88.
- 34 Wiebe CB, Silver JG, Larjava HS. Early-onset periodontitis associated with Weary-Kindler syndrome: a case report. *J Periodontol* 1996; **67**: 1004–1010.
- 35 Lai-Cheong JE, McGrath JA. Kindler syndrome. *Dermatol Clin* 2010; **28**: 119–124.
- 36 Kaslick RS, Brustein HC. Epidermolysis bullosa. Review of the literature and report of a case. *Oral Surg Oral Med Oral Pathol* 1961; **14**: 1315–1330.
- 37 Wright JT. Epidermolysis bullosa: dental and anesthetic management of two cases. *Oral Surg Oral Med Oral Pathol* 1984; **57**: 155–157.
- 38 Wright JT. Comprehensive dental care and general anesthetic management of hereditary epidermolysis bullosa. A review of fourteen cases. *Oral Surg Oral Med Oral Pathol* 1990; **70**: 573–578.
- 39 Lee H, Al Mardini M, Ercoli C, Smith MN. Oral rehabilitation of a completely edentulous epidermolysis bullosa patient with an implant-supported prosthesis: a clinical report. *J Prosthet Dent* 2007; **97**: 65–69.
- 40 Muller F, Bergendal B, Wahlmann U, Wagner W. Implant-supported fixed dental prostheses in an edentulous patient with dystrophic epidermolysis bullosa. *Int J Prosthodont* 2010; **23**: 42–48.
- 41 Lindemeyer R, Wadenya R, Maxwell L. Dental and anaesthetic management of children with dystrophic epidermolysis bullosa. *Int J Paediatr Dent* 2009; **19**: 127–134.

- 42 Winter GB, Brook AH. Enamel hypoplasia and anomalies of the enamel. *Dent Clin North Am* 1975; **19**: 3–24.
- 43 Brooks JK, Bare LC, Davidson J, Taylor LS, Wright JT. Junctional epidermolysis bullosa associated with hypoplastic enamel and pervasive failure of tooth eruption: Oral rehabilitation with use of an overdenture. *Oral Surg Oral Med Oral Pathol Oral Radiol Endod* 2008; **105**: e24–e28.
- 44 Levy BP, Reeve CM, Kierland RR. The oral aspects of epidermolysis bullosa dystrophica: a case report. *J Periodontol* 1969; **40**: 431–434.
- 45 Haas CD. Epidermolysis bullosa dystrophica. Report of a case. *Oral Surg Oral Med Oral Pathol* 1968; **26**: 291–295.
- 46 Buduneli E, Ilgenli T, Buduneli N, Ozdemir F. Acellular dermal matrix allograft used to gain attached gingiva in a case of epidermolysis bullosa. *J Clin Periodontol* 2003; **30**: 1011–1015.
- 47 Brain JH, Paul BF, Assad DA. Periodontal plastic surgery in a dystrophic epidermolysis bullosa patient: review and case report. *J Periodontol* 1999; **70**: 1392–1396.
- 48 Pacheco W, Marques de Sousa AR. Orthodontic treatment of a patient with recessive dystrophic epidermolysis bullosa: a case report. *Spec Care Dentist* 2008; **28**: 136–139.
- 49 Wright JT, Childers NK, Evans KL, Johnson LB, Fine JD. Salivary function of persons with hereditary epidermolysis bullosa. *Oral Surg Oral Med Oral Pathol* 1991; **71**: 553–559.
- 50 Shah H, McDonald F, Lucas V, Ashley P, Roberts G. A cephalometric analysis of patients with recessive dystrophic epidermolysis bullosa. *Angle Orthod* 2002; **72**: 55–60.
- 51 Serrano-Martinez MC, Bagan JV, Silvestre FJ, Viguer MT. Oral lesions in recessive dystrophic epidermolysis bullosa. *Oral Dis* 2003; **9**: 264–268.
- 52 Pizzo G, Scardina GA, Messina P. Effects of a nonsurgical exercise program on the decreased mouth opening in patients with systemic scleroderma. *Clin Oral Investig* 2003; **7**: 175–178.
- 53 Carroll DL, Stephan MJ, Hays GL. Epidermolysis bullosa – review and report of case. *J Am Dent Assoc* 1983; **107**: 749–751.
- 54 Larrazabal-Moron C, Boronat-Lopez A, Penarrocha-Diago M, Penarrocha-Diago M. Oral rehabilitation with bone graft and simultaneous dental implants in a patient with epidermolysis bullosa: a clinical case report. *J Oral Maxillofac Surg* 2009; **67**: 1499–1502.
- 55 Penarrocha M *et al.* Complete fixed prostheses over implants in patients with oral epidermolysis bullosa. *J Oral Maxillofac Surg* 2007; **65**: 103–106.
- 56 Fewtrell MS *et al.* Bone mineralization in children with epidermolysis bullosa. *Br J Dermatol* 2006; **154**: 959–962.
- 57 Lin YC, Golianu B. Anesthesia and pain management for pediatric patients with dystrophic epidermolysis bullosa. *J Clin Anesth* 2006; **18**: 268–271.
- 58 Fine JD *et al.* The classification of inherited epidermolysis bullosa (EB): report of the Third International Consensus Meeting on Diagnosis and Classification of EB. *J Am Acad Dermatol* 2008; **58**: 931–950.
- 59 Sedano HO, Gorlin RJ. Epidermolysis bullosa. *Oral Surg Oral Med Oral Pathol* 1989; **67**: 555–563.
- 60 Niemi KM, Sommer H, Kero M, Kanerva L, Haltia M. Epidermolysis bullosa simplex associated with muscular dystrophy with recessive inheritance. *Arch Dermatol* 1988; **124**: 551–554.
- 61 Sadler E *et al.* [Dental alterations in junctional epidermolysis bullosa – report of a patient with a mutation in the LAMB3-gene]. *J Dtsch Dermatol Ges* 2005; **3**: 359–363.
- 62 Arwill T, Olsson O, Bergenholtz A. Epidermolysis bullosa hereditaria. 3. A histologic study of changes in teeth in the polydysplastic dystrophic and lethal forms. *Oral Surg Oral Med Oral Pathol* 1965; **19**: 723–744.
- 63 Gardner DG, Hudson CD. The disturbances in odontogenesis in epidermolysis bullosa hereditaria letalis. *Oral Surg Oral Med Oral Pathol* 1975; **40**: 483–493.
- 64 Brain EB, Wigglesworth JS. Developing teeth in epidermolysis bullosa hereditaria letalis. A histological study. *Br Dent J* 1968; **124**: 255–260.
- 65 Lazarus GS. Collagenase and connective tissue metabolism in epidermolysis bullosa. *J Invest Dermatol* 1972; **58**: 242–248.
- 66 Wright JT, Johnson LB, Fine JD. Development defects of enamel in humans with hereditary epidermolysis bullosa. *Arch Oral Biol* 1993; **38**: 945–955.
- 67 Wright JT, Hall KI, Deaton TG, Fine JD. Structural and compositional alteration of tooth enamel in hereditary epidermolysis bullosa. *Connect Tissue Res* 1996; **34**: 271–279.
- 68 McGrath JA *et al.* Compound heterozygosity for a dominant glycine substitution and a recessive internal duplication mutation in the type XVII collagen gene results in junctional epidermolysis bullosa and abnormal dentition. *Am J Pathol* 1996; **148**: 1787–1796.
- 69 Laimer M, Nischler E. *Intraoral disease in Life with Epidermolysis Bullosa (EB): Etiology Diagnosis, Multidisciplinary Care and Therapy*. Wien: Springer, 2008: 150–166.
- 70 Bauer JW, Lanschuetzer C. Type XVII collagen gene mutations in junctional epidermolysis bullosa and prospects for gene therapy. *Clin Exp Dermatol* 2003; **28**: 53–60.
- 71 Jonkman MF, Pas HH, Nijenhuis M, Kloosterhuis G, Steege G. Deletion of a cytoplasmic domain of integrin beta4 causes epidermolysis bullosa simplex. *J Invest Dermatol* 2002; **119**: 1275–1281.
- 72 Olague-Marchan M *et al.* A disease-associated glycine substitution in BP180 (type XVII collagen) leads to a local destabilization of the major collagen triple helix. *Matrix Biol* 2000; **19**: 223–233.

- 73 Hintner H, Wolff K. Generalized atrophic benign epidermolysis bullosa. *Arch Dermatol* 1982; **118**: 375–384.
- 74 Wright JT, Fine JD, Johnson LB, Steinmetz TT. Oral involvement of recessive dystrophic epidermolysis bullosa inversa. *Am J Med Genet* 1993; **47**: 1184–1188.
- 75 Pearson RW, Paller AS. Dermolytic (dystrophic) epidermolysis bullosa inversa. *Arch Dermatol* 1988; **124**: 544–547.
- 76 Grover S. Generalised recessive dystrophic epidermolysis bullosa in two sisters. *Indian J Dermatol Venereol Leprol* 2001; **67**: 205–206.
- 77 Reed WB *et al.* Epidermolysis bullosa dystrophica with epidermal neoplasms. *Arch Dermatol* 1974; **110**: 894–902.
- 78 Kramer SM, Zillmann G, Muñoz A, San Pedro P. *Análisis de las características bucodentarias de pacientes con diferentes subtipos de Epidermolisis Bullosa*. Santiago, Chile: Universidad de Chile, 2006.
- 79 Dougherty ME, Warden GD. A thirty-year review of oral appliances used to manage microstomia, 1972 to 2002. *J Burn Care Rehabil* 2003; **24**: 418–431.
- 80 Fine JD *et al.* Premature Death in Inherited Epidermolysis Bullosa. In: *Epidermolysis Bullosa. Clinical Epidemiologic, and Laboratory Advances and the Findings of the National Epidermolysis Bullosa Registry*. Eds: Jo-David Fine, Eugene A. Bauer, Joseph McGuire and Alan Moshell. Baltimore, Maryland: The Johns Hopkins University Press, 1999: 206–224.
- 81 Martinez L, Goodman P, Crow WN. Squamous cell carcinoma of the maxillary sinus and palate in epidermolysis bullosa: CT demonstration. *J Comput Assist Tomogr* 1992; **16**: 317–319.
- 82 Liversidge HM, Kosmidou A, Hector MP, Roberts GJ. Epidermolysis bullosa and dental developmental age. *Int J Paediatr Dent* 2005; **15**: 335–341.
- 83 Kostara A, Roberts GJ, Gelbier M. Dental maturity in children with dystrophic epidermolysis bullosa. *Pediatr Dent* 2000; **22**: 385–388.
- 84 Mars M, Houston WJ. A preliminary study of facial growth and morphology in unoperated male unilateral cleft lip and palate subjects over 13 years of age. *Cleft Palate J* 1990; **27**: 7–10.
- 85 Wiebe CB *et al.* Clinical and microbiologic study of periodontitis associated with Kindler syndrome. *J Periodontol* 2003; **74**: 25–31.
- 86 Lotem M *et al.* Kindler syndrome complicated by squamous cell carcinoma of the hard palate: successful treatment with high-dose radiation therapy and granulocyte-macrophage colony-stimulating factor. *Br J Dermatol* 2001; **144**: 1284–1286.
- 87 Wiebe CB *et al.* Kindler syndrome and periodontal disease: review of the literature and a 12-year follow-up case. *J Periodontol* 2008; **79**: 961–966.
- 88 Ricketts DN, Morgan CL, McGregor JM, Morgan PR. Kindler syndrome: a rare cause of desquamative lesions of the gingiva. *Oral Surg Oral Med Oral Pathol Oral Radiol Endod* 1997; **84**: 488–491.
- 89 Ashton GH. Kindler syndrome. *Clin Exp Dermatol* 2004; **29**: 116–121.
- 90 Hacham-Zadeh S, Garfunkel AA. Kindler syndrome in two related Kurdish families. *Am J Med Genet* 1985; **20**: 43–48.
- 91 Fine JD, Bauer EA, McGuire J, Moshell A. *Epidermolysis Bullosa Clinical, Epidemiologic, and Laboratory Advances and the Findings of the National Epidermolysis Bullosa Registry*. Baltimore, Maryland: The Johns Hopkins University Press, 1999.
- 92 Pearson RW. Studies on the pathogenesis of epidermolysis bullosa. *J Invest Dermatol* 1962; **39**: 551–575.
- 93 Fine JD *et al.* Revised clinical and laboratory criteria for subtypes of inherited epidermolysis bullosa. A consensus report by the Subcommittee on Diagnosis and Classification of the National Epidermolysis Bullosa Registry. *J Am Acad Dermatol* 1991; **24**: 119–135.
- 94 Fine JD *et al.* Revised classification system for inherited epidermolysis bullosa: report of the Second International Consensus Meeting on diagnosis and classification of epidermolysis bullosa. *J Am Acad Dermatol* 2000; **42**: 1051–1066.
- 95 Castillo RO, Davies YK, Lin YC, Garcia M, Young H. Management of esophageal strictures in children with recessive dystrophic epidermolysis bullosa. *J Pediatr Gastroenterol Nutr* 2002; **34**: 535–541.
- 96 Ingen-Housz-Oro S, Blanchet-Bardon C, Vrillat M, Dubertret L. Vitamin and trace metal levels in recessive dystrophic epidermolysis bullosa. *J Eur Acad Dermatol Venereol* 2004; **18**: 649–653.
- 97 Fine JD, Johnson LB, Weiner M, Suchindran C. Gastrointestinal complications of inherited epidermolysis bullosa: cumulative experience of the National Epidermolysis Bullosa Registry. *J Pediatr Gastroenterol Nutr* 2008; **46**: 147–158.
- 98 Haynes L. *Nutritional Support for Children with Epidermolysis Bullosa in Life with Epidermolysis Bullosa (EB): etiology, Diagnosis, Multidisciplinary Care and Therapy*. Wien: Springer, 2008: 258–277.
- 99 Sidwell RU, Yates R, Atherton D. Dilated cardiomyopathy in dystrophic epidermolysis bullosa. *Arch Dis Child* 2000; **83**: 59–63.
- 100 Langan SM, Williams HC. A systematic review of randomized controlled trials of treatments for inherited forms of epidermolysis bullosa. *Clin Exp Dermatol* 2009; **34**: 20–25.
- 101 Ames WA, Mayou BJ, Williams KN. Anaesthetic management of epidermolysis bullosa. *Br J Anaesth* 1999; **82**: 746–751.
- 102 van Scheppingen C, Lettinga AT, Duipmans JC, Maathuis CG, Jonkman MF. Main problems experienced by children with epidermolysis bullosa: a qualitative study with semi-structured interviews. *Acta Derm Venereol* 2008; **88**: 143–150.
- 103 Frew JW, Martin LK, Nijsten T, Murrell DF. Quality of life evaluation in epidermolysis bullosa (EB) through the development of the QOLEB questionnaire: an EB-specific quality of life instrument. *Br J Dermatol* 2009; **161**: 1323–1330.